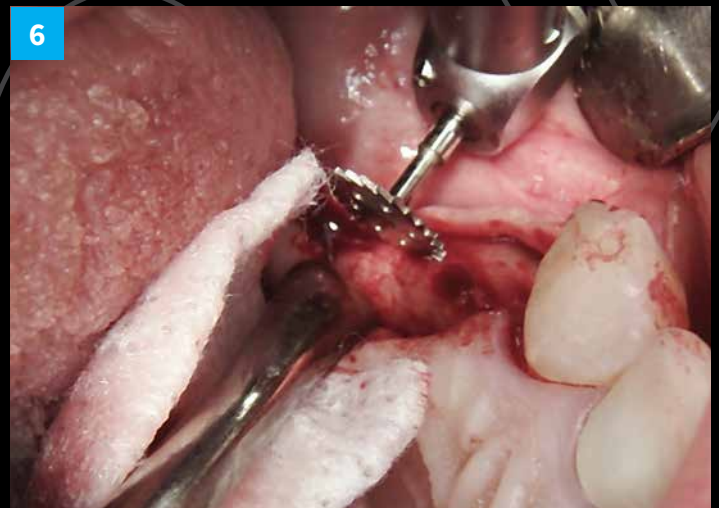
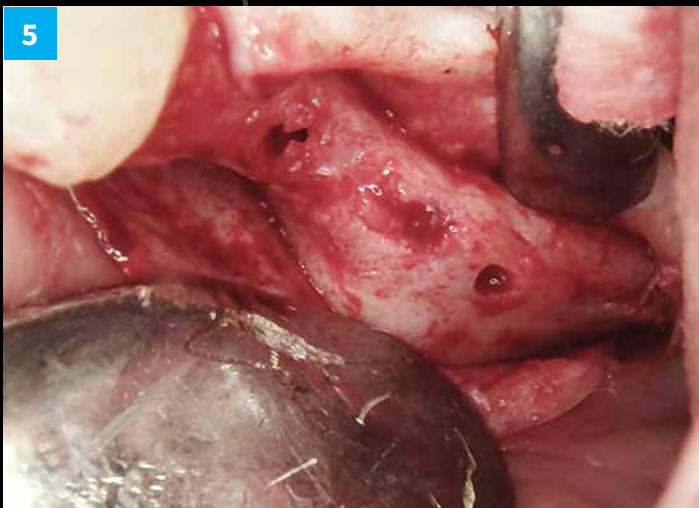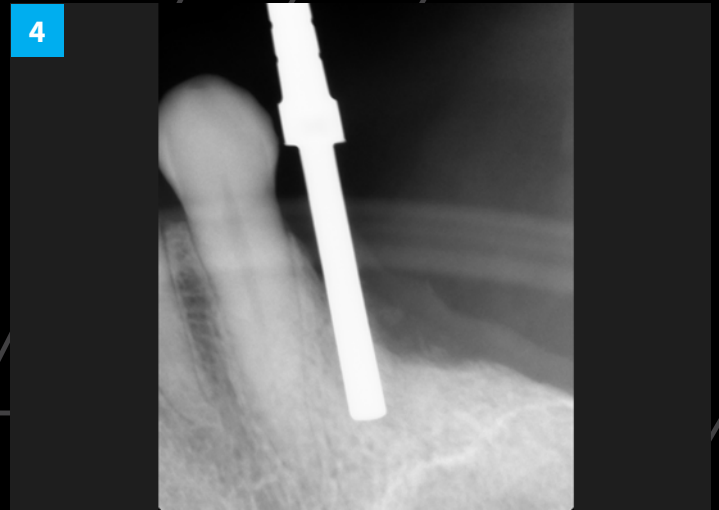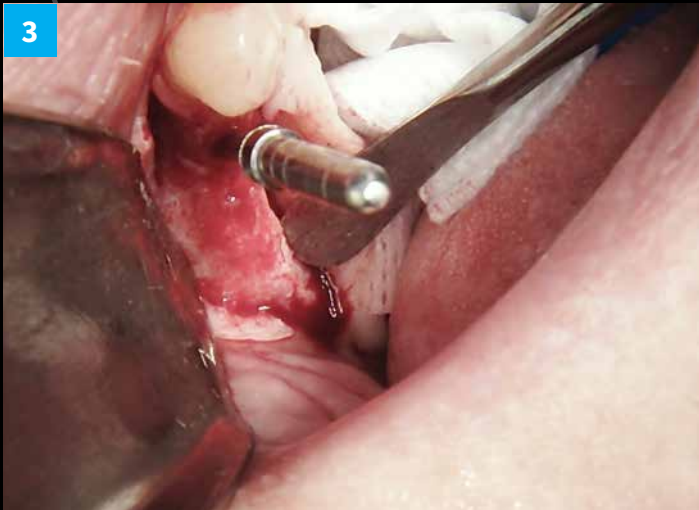
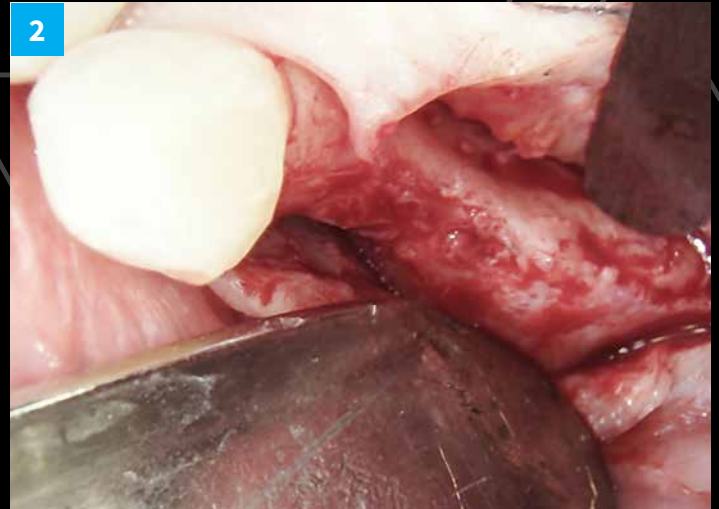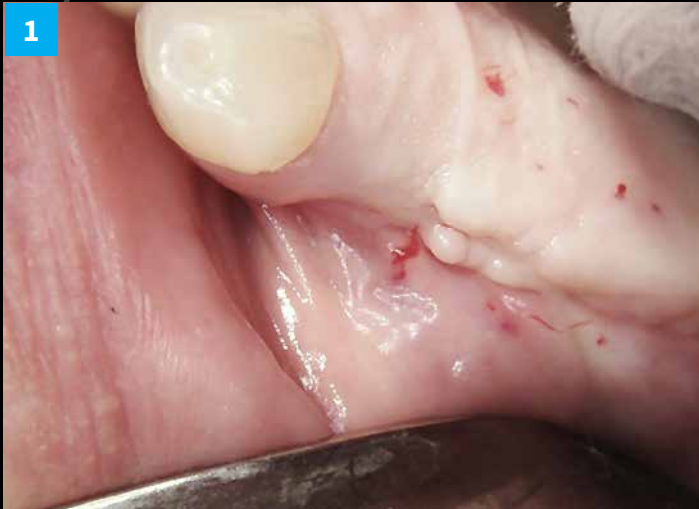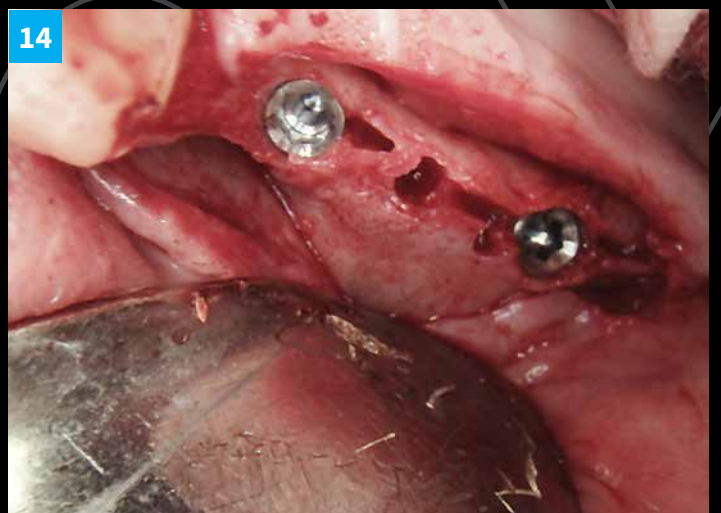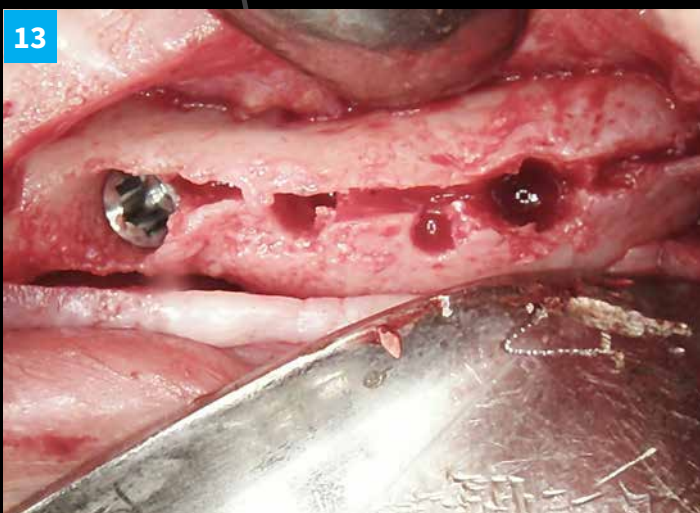
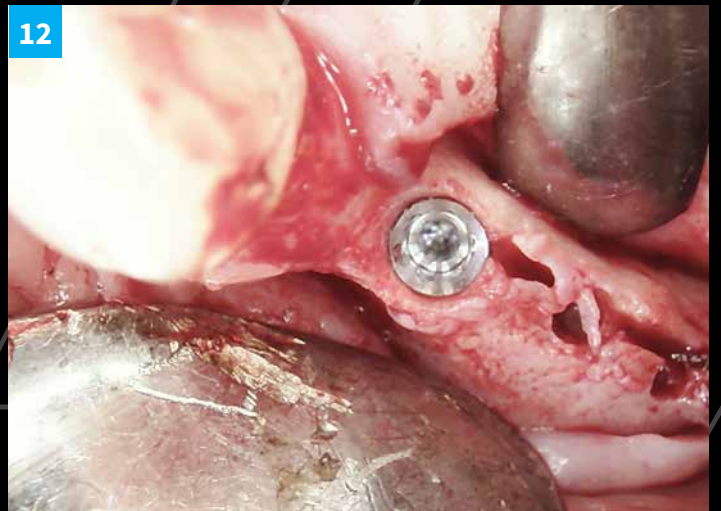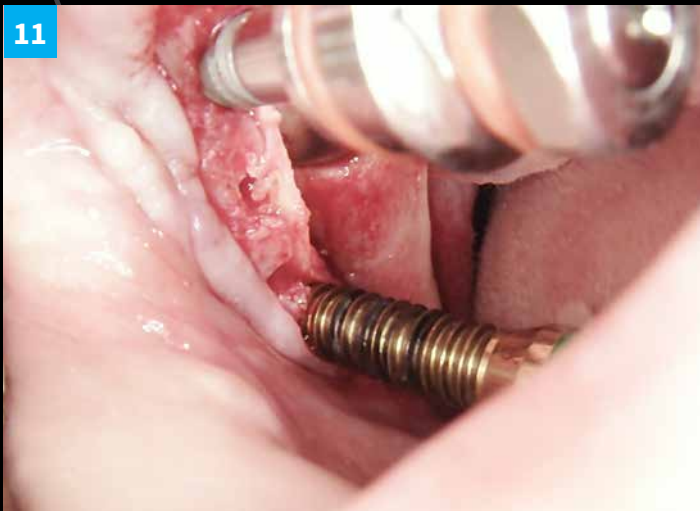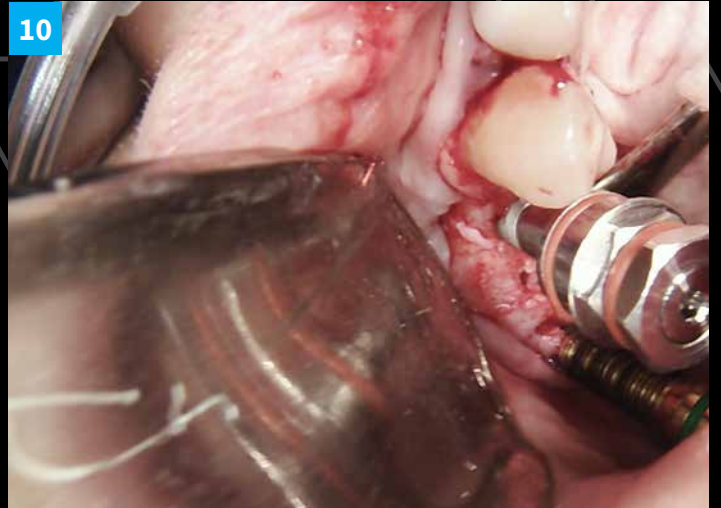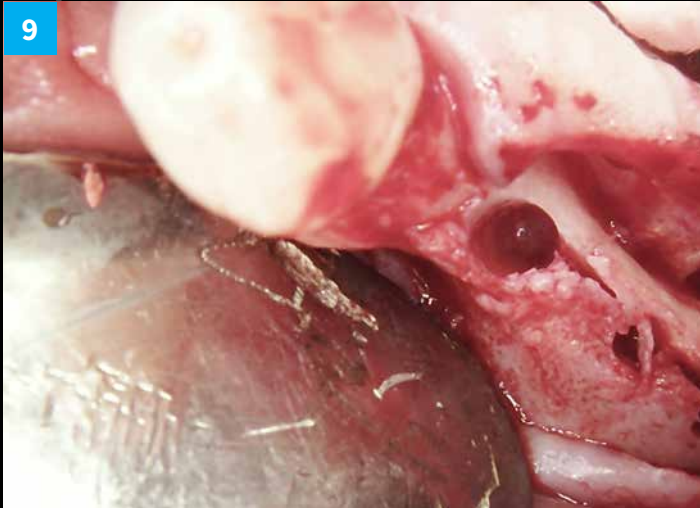
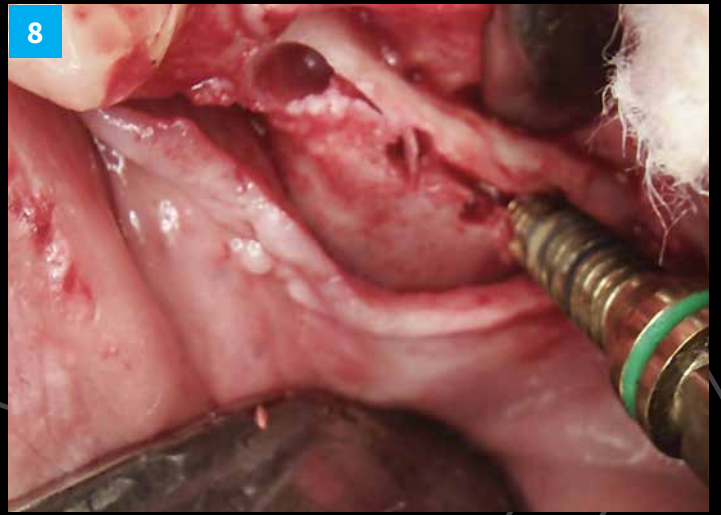
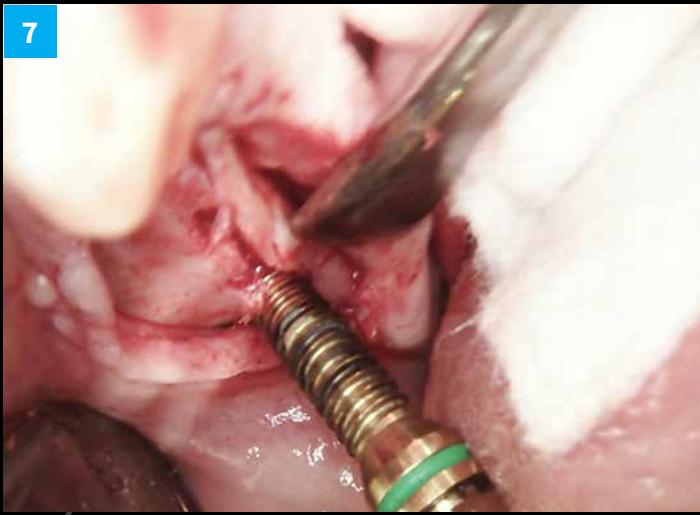
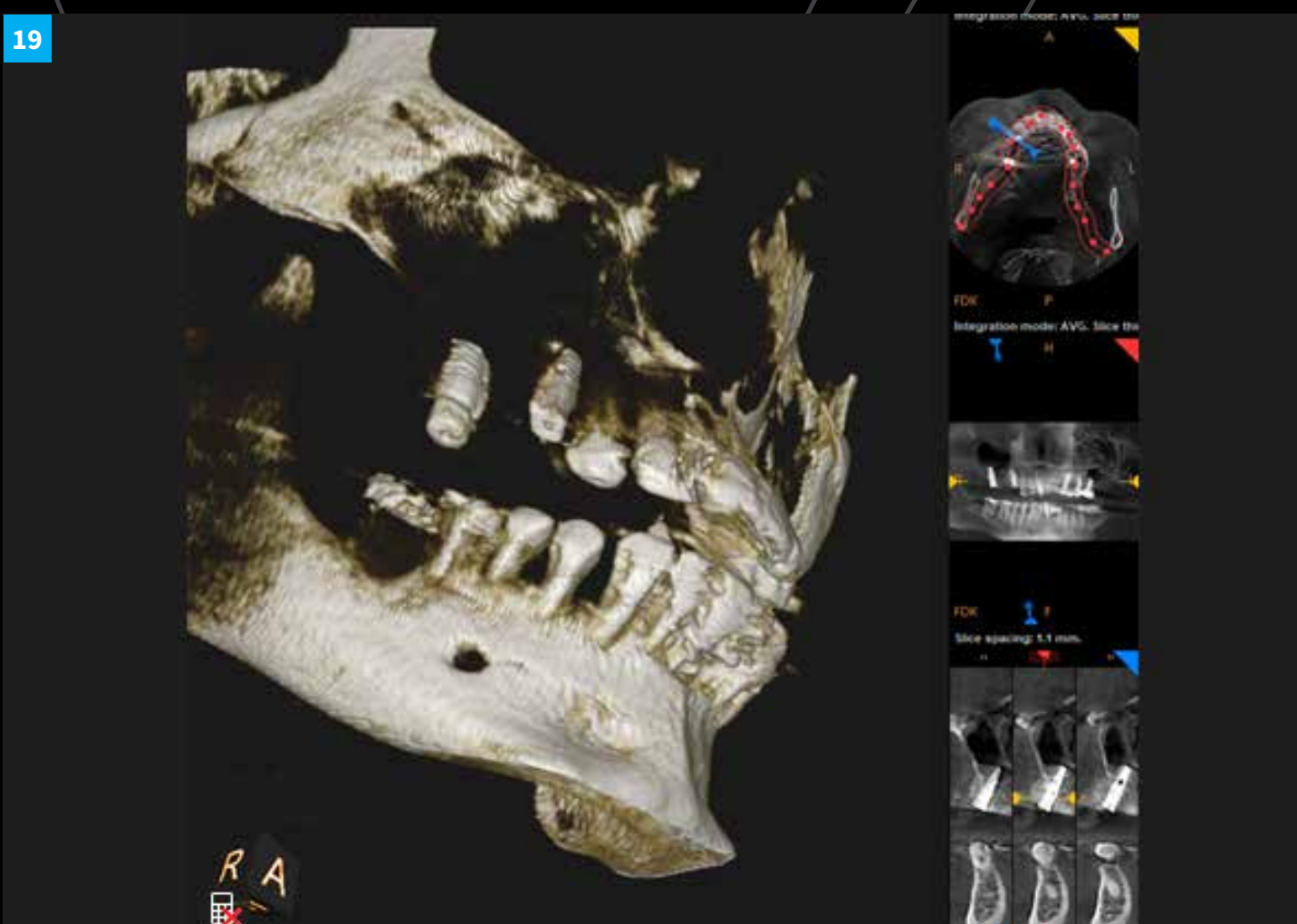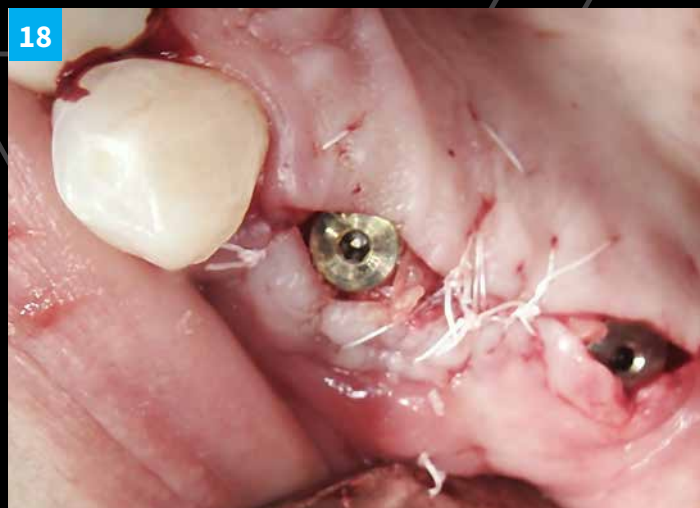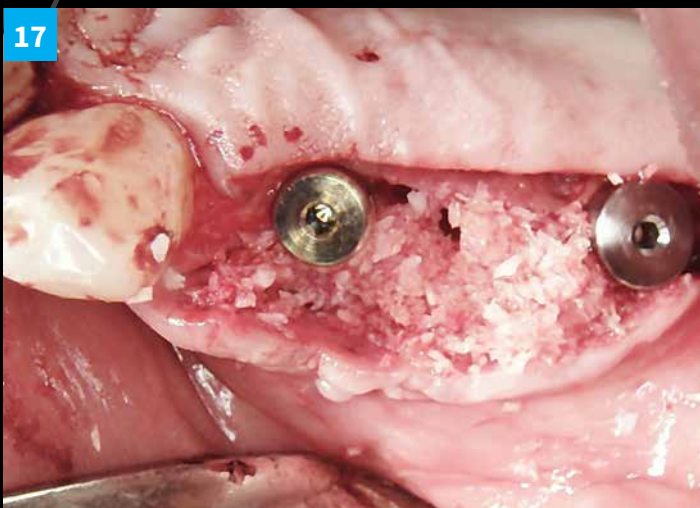


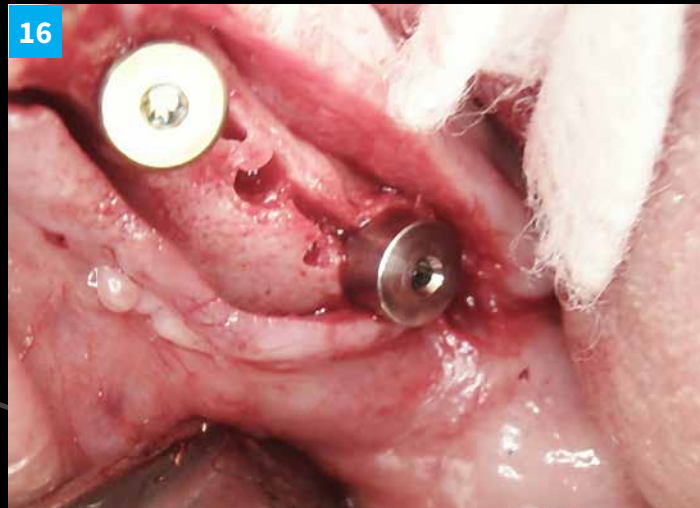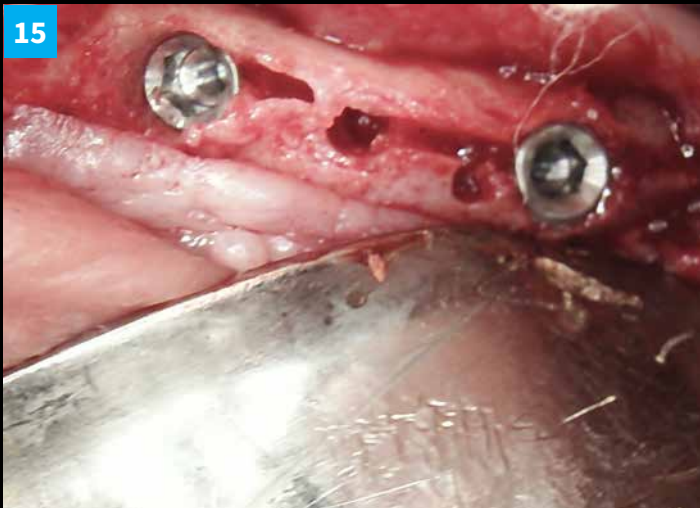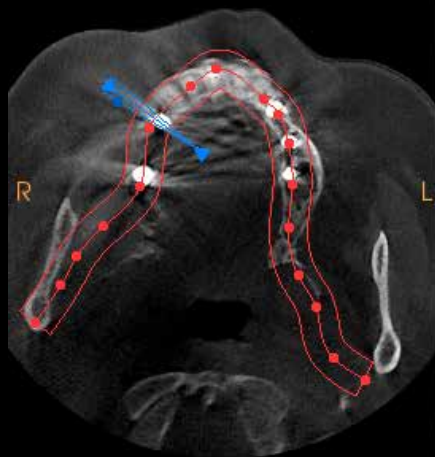
## CLINICAL CASE

# Sinus implantation with ridge expansion



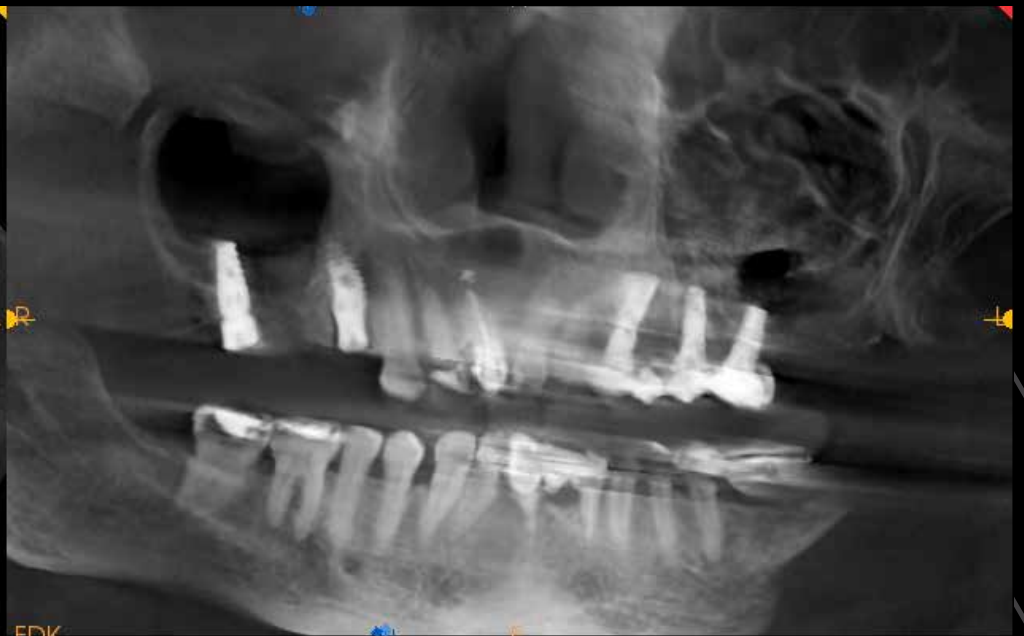





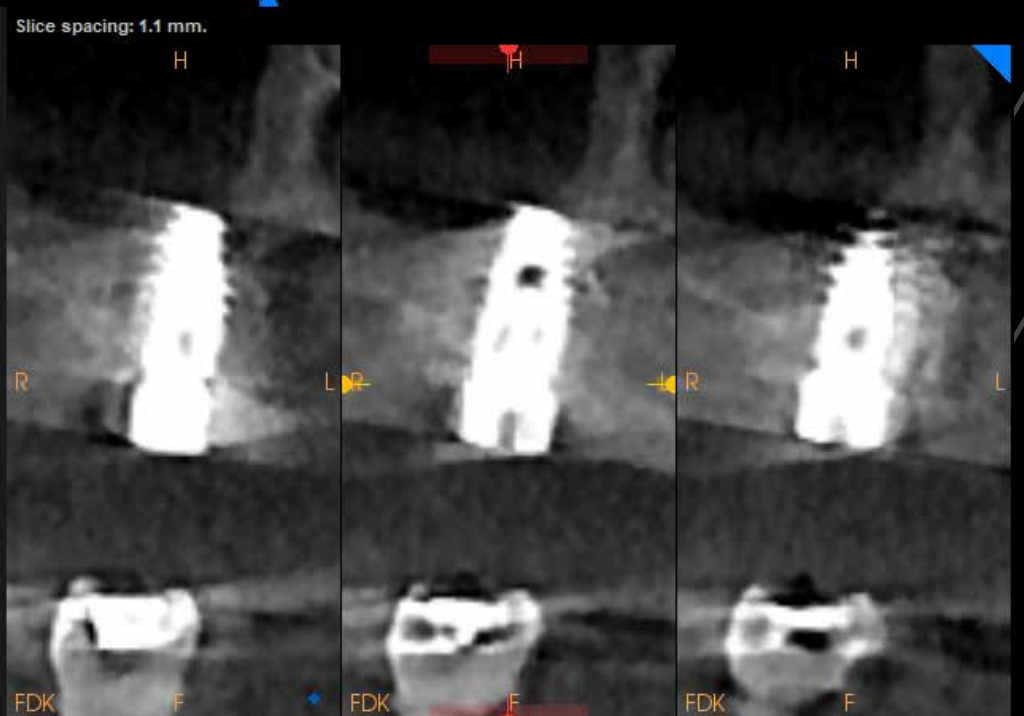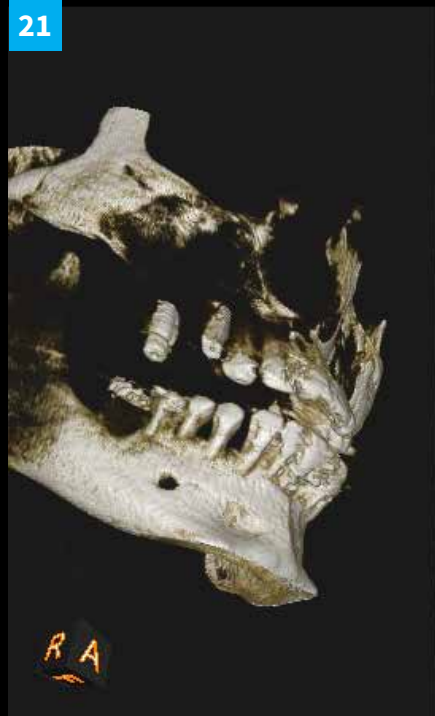
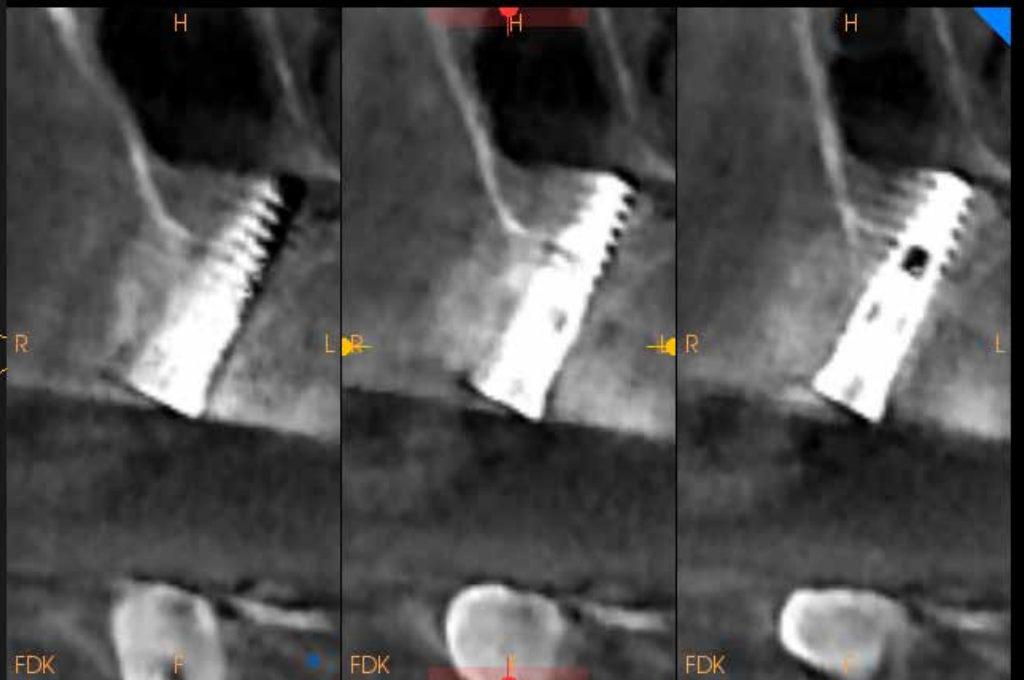
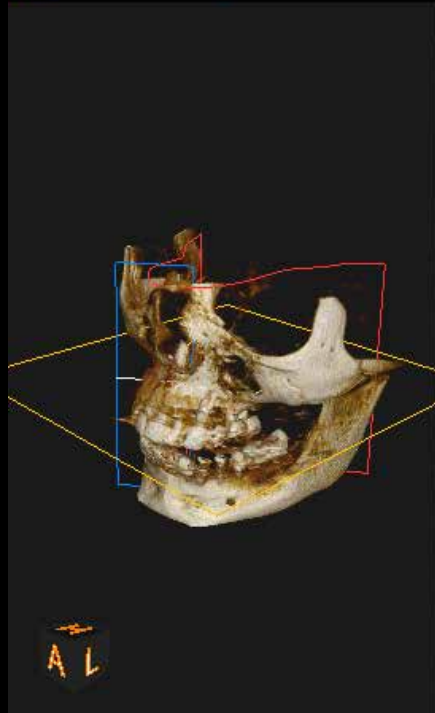
FDK

P



FDK

Slice spacing: 1.1 mm.



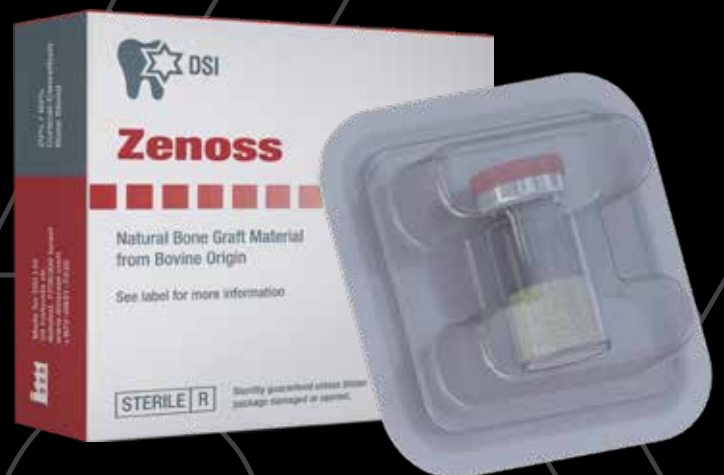Case by a kind courtesy of Dr. Carmy Michael,  
Dental Implant Institute of The West Coast.  
[www.diiwc.com](http://www.diiwc.com)



Used in the case: Maxillary Ridge expansion with 2 DSI Premium implants (3.5x13 for premolar, 5x10 for molar) and crestal sinus lift plus 2 immediate implants with healing abutments & buccal bone graft.

PTFE sutures after tissue release.

Used Ridge expansion kit plus implant positioning kit and finalized xenograft with PRF.



- We will establish a true mentee-mentor partnership with specific goals to be accomplished throughout the course of the mentoring program.
- Many offices have greatly benefited from mutual cooperation.
- We've been there, Done that and now we are passing what we have to our partners, Successes, Failures, Advances, Changes and Pearls.
- Come join us in the wonderful world of dental implantology.
- Treat yourself and your staff to a truly priceless journey.

<https://www.diiwc.com/courses>