Ocular Immunology and Inflammation

ISSN: (Print) (Online) Journal homepage: https://www.tandfonline.com/loi/ioii20

Surgical Outcomes of Modified CO_2 Laser-assisted Sclerectomy for Uveitic Glaucoma

Junyan Xiao, Chan Zhao, Yang Zhang, Anyi Liang, Yi Qu, Gangwei Cheng & Meifen Zhang

To cite this article: Junyan Xiao, Chan Zhao, Yang Zhang, Anyi Liang, Yi Qu, Gangwei Cheng & Meifen Zhang (2021): Surgical Outcomes of Modified CO_2 Laser-assisted Sclerectomy for Uveitic Glaucoma, Ocular Immunology and Inflammation, DOI: 10.1080/09273948.2021.1924385

To link to this article: https://doi.org/10.1080/09273948.2021.1924385

Published online: 13 May 2021.

OCULAR IMMUNOLOGY AND INFLAMMATION
https://doi.org/10.1080/09273948.2021.1924385

Taylor & Francis
Taylor & Francis Group

ORIGINAL ARTICLE

Surgical Outcomes of Modified CO_2 Laser-assisted Sclerectomy for Uveitic Glaucoma

Junyan Xiao, MD[a], Chan Zhao, MD[a], Yang Zhang, MD[a], Anyi Liang, MD[a], Yi Qu, MD[a,b], Gangwei Cheng, MD[a], and Meifen Zhang, MD[a]

[a]Department of Ophthalmology, Peking Union Medical College Hospital, Chinese Academy of Medical Sciences and Peking Union Medical College, Beijing, China; [b]Department of Ophthalmology, Peking University Third Hospital, Beijing, China

ABSTRACT

Purpose: To evaluate the clinical safety and efficacy of modified CO_2 laser-assisted sclerectomy surgery (CLASS) in patients with uveitic glaucoma (UG) using primary open-angle glaucoma (POAG) patients for a comparison.
Methods: This retrospective study included UG and POAG patients from the modified CLASS Study Group database. Intraocular pressure (IOP) and the number of glaucoma medications were compared between groups by the Wilcoxon test. The Kaplan–Meier method was used for survival analysis; complete success was defined as 5≤ IOP≤18 mmHg and a ≥ 20% reduction in IOP from baseline without medication.
Results: Twenty-three and 25 eyes in UG and POAG groups were included. At the 12-month visit in both groups, the mean IOP and mean number of IOP-lowering medications were significantly reduced compared to baseline, with complete success rates of 60.9% and 64.0% in the UG and POAG groups ($P = .859$).
Conclusions: Modified CLASS yields similar outcomes for patients with UG and POAG.

ARTICLE HISTORY
Received 3 June 2020
Revised 5 April 2021
Accepted 26 April 2021

KEYWORDS
Nonpenetrating deep sclerectomy; CO_2 laser; uveitic glaucoma; intraocular pressure; surgical management

The mechanisms underlying increased intraocular pressure (IOP) in patients with glaucoma associated with uveitis are diverse and complicated. These mechanisms include mechanical clogging of the trabecular meshwork (TM) by inflammatory cells and synechia closure of the angle caused by chronic inflammation, trabeculitis, and steroid responses.[1–3] The management of uveitic glaucoma (UG) can be unpredictable and difficult because it requires a careful diagnosis and adequate control of both IOP and inflammation.[4] Considering that UG presents earlier than primary open-angle glaucoma (POAG), patients with UG tend to be younger and require many more years of IOP control.

Trabeculectomy is the main procedure performed to treat UG,[5] and it is associated with many potential vision-threatening complications.[6] The goals of the nonpenetrating deep sclerectomy (NPDS) procedure, which was first described by Krasnov[7] in 1964, are to reduce the risk of these complications by preserving the integrity of the trabeculo-Descemet membrane (TDM) and stabilize the anterior chamber (AC).[8] The NPDS procedure is technically difficult to perform manually, which has limited its popularity.[9] CO_2 laser-assisted sclerectomy surgery (CLASS) is an improved version of NPDS that uses a CO_2 laser, which is precise and easily strips the deep sclera, unroofs the Schlemm's canal (SC) and leaves the TDM thin enough for aqueous humor (AH) percolation. Perforations can be avoided by a CO_2 laser because of its unique characteristics and effectiveness in ablating only dry tissues.[10] In addition, the high incidence rates of peripheral anterior synechiae (PAS) and iris incarceration after CLASS have been reported.[11] Therefore, we modified and standardized the CLASS procedure to improve the efficacy of CLASS, reduce the rate of postoperative complications, and adapt to the features of East Asian patients, including a crowded anterior segment (the central AC is twice the thickness of the cornea, and the peripheral AC is less than 1/4 of the corneal thickness)[12] and refractory glaucoma with uncontrollable IOP under maximal tolerable medication.[13]

To the best of our knowledge, this study is one of the first pilot studies that evaluated the safety and efficacy of modified CLASS in patients with UG and compared the outcomes between patients with UG and POAG.

Materials and methods

This was a single-center retrospective comparative study. The protocol was approved by the Institutional Review Board of the Peking Union Medical College Hospital (PUMCH) (S-K1363-3) and was performed in accordance with the tenets of the Declaration of Helsinki.

Patients

The records of Chinese patients with UG and POAG who underwent modified CLASS between June 2015 and August 2018 at PUMCH were reviewed. A total of 48 consecutive cases with medically uncontrolled glaucoma secondary to UG or POAG that had been followed up for at least 1 year were included. The following inclusion and exclusion criteria were adopted to improve the diagnostic accuracy and minimize the potential biases introduced by confounding factors involved in the evaluation of modified CLASS.

The inclusion criteria were as follows: (1) glaucomatous changes that include optic disc rim narrowing, a retinal nerve fiber layer defect (RNFLD), and/or a glaucomatous visual field (GVF) and open angle, secondary causes excluded for the POAG group; (2) glaucomatous changes that include optic disc rim

CONTACT Gangwei Cheng ChengGW@pumch.cn Meifen Zhang meifen_zhang@hotmail.com Department of Ophthalmology, Peking Union Medical College Hospital, Chinese Academy of Medical Sciences and Peking Union Medical College, No.1 Shuaifuyuan, Dongcheng District, Beijing 100730, China.

narrowing, RNFLD and/or a GVF and high IOP after the diagnosis of uveitis for the UG group; and (3) no active inflammation for at least 3 months before the modified CLASS surgery. The exclusion criteria were as follows: (1) evidence suggesting the presence of other glaucoma-associated etiologies; (2) PAS of more than 180 degrees (PAS in the preferred superior surgical quadrant were excluded unless they were dot adhesions); (3) a history of any other eye surgery during the past 6 months; (4) combined CLASS surgery; (5) corneal opacity or opaque refractive media that may interfere with optic nerve evaluations; and (6) iris or chamber lesions (e.g., iris or angle neovascularization, foreign body, and tumor).

The baseline assessments included a best-corrected visual acuity (BCVA) examination, Goldmann applanation tonometry, an anterior segment slit-lamp examination, gonioscopy using a Goldmann 1-mirror lens at high magnification (×16), a visual field examination (Octopus 101 program G1, Interzeag AG, Schlieren, Switzerland), and direct or indirect fundoscopy. All postoperative details for the operations were recorded until the last follow-up visit or until a secondary glaucoma surgery was performed. The magnitude of reduction in IOP was the primary outcome. The Kaplan–Meier survival analysis results, the magnitude of reduction in the number of glaucoma medications, and surgical complications were the secondary outcomes. In brief, surgical success was defined as an IOP controlled between 5 and 18 mm Hg and a reduction in IOP by more than 20% of the baseline. Complete success was defined as success achieved without medications, and qualified success was defined as success achieved with or without adjunct medications.

Surgical procedure

Preoperative management

For the patients in both groups, after the measurement of baseline IOP, all IOP-lowering eye drops were stopped preoperatively and replaced by systematic medications. For the UG group, oral steroids were given to all patients at a dose equal to 1 mg of prednisone per kilogram of body weight on the day of surgery and gradually tapered based on the cellular response in the AC and type of uveitis. For the POAG group, oral steroids were given to a proportion of the patients to protect the optic nerve and visual function[14,15] and stopped within 72 hours. Laser peripheral iridectomy (LPI) plus argon laser peripheral iridoplasty (ALPI) corresponding to the ablation area was performed within 1–3 days before the procedure using a LUMENIS® 635 nm diode laser (Lumenis Inc., Salt Lake City, UT, USA) and a VISULAS® 532 s diode laser (Carl Zeiss Meditec, Inc., Dublin, CA, USA). Before the laser procedures, pilocarpine eye drops (2%) were given 3 times at an interval of 10 minutes. The superior quadrant of the iris with wide gonio was selected as the site of LPI. The locations with PAS and heavy pigmentation were avoided. LPI was performed extremely close to the root of the iris and centered at the designed percolation area.

Intraoperative procedures

Modified CLASS (OT-134-IOPtiMate, IOPtima Ltd., Ramat Gan, Israel) was performed under subconjunctival anesthesia with 2% lidocaine without epinephrine. In particular, a fornix-based conjunctival flap was created, and the extra Tenon capsule was dissected. A scleral flap with a scleral thickness of 1/3 to 1/2 and size of 5 × 5 mm^2 was created. At the surgeon's discretion, surgical sponges soaked in 5-fluorouracil (5-FU) (25 mg/mL) were applied under the conjunctiva for 2–3 minutes and under the scleral flap for 4–6 minutes and then irrigation with at least 30 mL of balanced salt solution (BSS) was performed. The site and shape of the desired scanning area were set, and a focused laser (HeNe) beam was used to mark the boundaries. To form a reservoir for fluid outflow (subscleral lake), the CO_2 laser was repeatedly applied with time intervals of 2–3 seconds. The energy setting was similar for all the patients, which was approximately 22 watts. The subscleral lake was 4.0 mm × 2.21 ± 0.30 mm in size, and its thickness was approximately 90% of the scleral thickness. 5-FU was applied again on the scleral floor for 2 minutes and rinsed off thoroughly with BSS. The presence of a particularly high IOP warranted the use of paracentesis to gradually reduce IOP. The CO_2 laser beam was subsequently applied over the surgical limbus to unroof the Schlemm's canal (size 1.5 × 4 mm) until fluid percolation was seen, and then the laser beam was moved forward to partially ablate the TDW (size 1 × 4 mm) to make the TDW thinner and more permeable. The scleral flap was tightly sutured using two 10–0 nylon adjustable sutures. An experienced glaucoma specialist (GW Cheng) performed all laser and surgical procedures.

Postoperative management

Postoperatively, the patients were treated with topical antibiotics and prednisolone eye drops, the doses of which were gradually adjusted and tapered to the preoperative maintenance dose by uveitis specialists. In addition, 2% pilocarpine was used each night for at least 4 weeks. Adjustable sutures were released transconjunctivally under a slit lamp at an early stage (<14 days) after the operation. The inner wall of the TM was assessed via gonioscopy at each visit. An experienced investigator performed ultrasound biomicroscopy (UBM) at 1 month, 3 months, and 12 months postoperatively. The probe frequency was 50 MHz, and the dB gain was adjusted to obtain the optimal image resolution and quality in the sclerectomy area. The size of the intrascleral lake at 1 month was compared with that at follow-up visits, and the morphological changes were divided into the following 4 types (Figure 1): stable (no change), mild reduction (≤30% change), moderate reduction (30% to 50% change), and severe reduction (>50% change, impending closure). If IOP exceeded 21 mm Hg and UBM revealed a severe reduction in the size of the intrascleral lake, then a needling procedure was performed, followed by a subconjunctival or subscleral injection of 5-FU (0.2 mL, 50 mg/mL). If the target IOP was not achieved, then laser goniopuncture (LGP) was performed with a Microruptor II neodymium: YAG (Nd:YAG) laser after severe PAS or iris incarceration was excluded postoperatively.

The need for LGP and needling was not considered an adverse event or a failure outcome because both are additional postoperative interventions commonly used for maintaining or augmenting operative results.[16,17] The number of times these interventions were performed and the time at which they were performed were recorded for each patient.

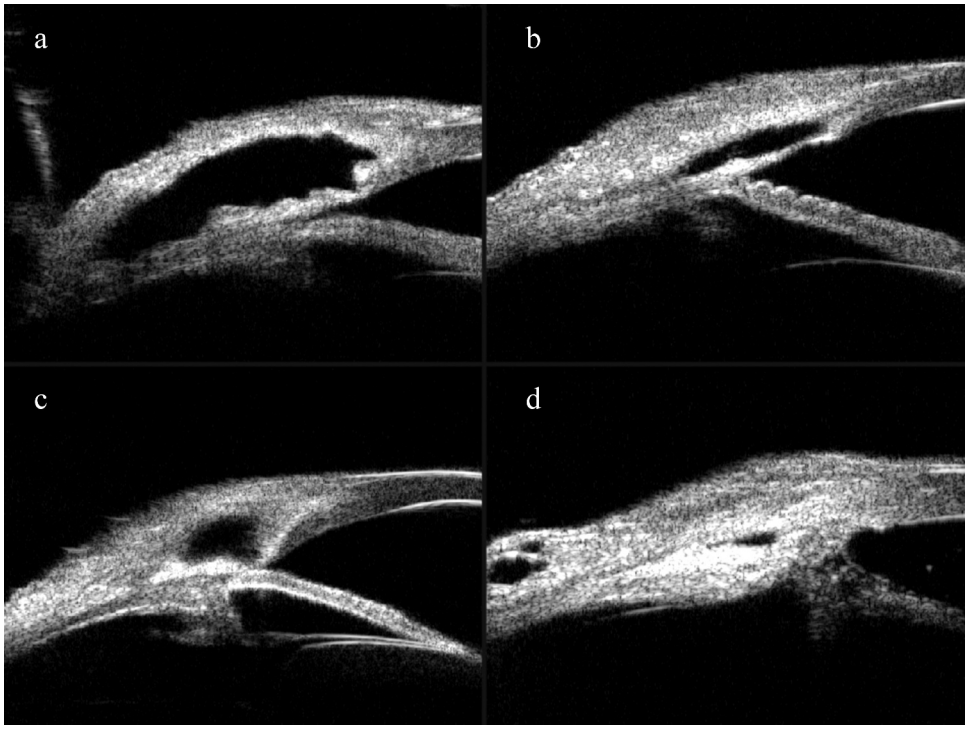

Figure 1. Four types of morphological changes in the intrascleral lake: (a), stable (no change); (b), mild reduction (≤30% change); (c), moderate reduction (30% to 50% change); and (d), severe reduction (>50% change, impending closure).

Statistical methods

SPSS Statistics Premium v21 (IBM Corp., Armonk, NY, USA) and Excel 2017 (Microsoft, Redmond, WA, USA) were used for all analyses. Baseline characteristics are expressed as the means (standard deviations), ranges, and percentages. The BCVA is expressed as the standard logarithmic value of visual acuity and was converted to the logarithm of the minimal angle of resolution unit of measurement for statistical analysis. Univariate associations between 2 categorical variables were analyzed using the chi-squared test or Fisher's exact test when any cell value was smaller than 5 during cross tabulation. Mann–Whitney U tests were performed to compare continuous parameters between 2 groups, and the Wilcoxon signed-rank test was used to compare continuous parameters within groups. Kaplan–Meier survival curves were constructed to describe the duration of complete and qualified success, and they were then compared using the log-rank test. $P < .05$ was considered statistically significant.

Results

Baseline characteristics

A total of 48 eyes of 40 patients, including 23 eyes of Chinese patients with UG and 25 eyes of Chinese patients with POAG, were included. The demographics and ophthalmologic history of the patients at baseline are presented in Table 1. The patients in the POAG group were significantly older than those in the UG group ($P < .01$). The groups were comparable with respect to sex.

Table 1. Demographics and ophthalmologic history of patients at baseline.

Characteristic	POAG n = 25	UG n = 23	P
Age (years)			<0.01
Mean ± SD	55.4 ± 11.6	37.3 ± 8.6	
Range	33–80	15–57	
Sex			1.00
Male	12 (60%)	12 (60%)	
Female	8 (40%)	8 (40%)	
Eye			0.79
OD	11 (44%)	11 (47.8%)	
OS	14 (56%)	12 (52.2%)	
Diagnosis			
POAG group	25		
UG group		23	
Idiopathic panuveitis		4 (17.4%)	
Vogt-Koyanagi-Harada syndrome		6 (26.1%)	
Bechet's disease		1 (4.3%)	
Posner-Schlossman syndrome		8 (34.8%)	
Fuchs' heterochromic iridocyclitis		4 (17.4%)	
Previous phacoemulsification	2 (8%)	9 (39.1%)	0.16
Previous SLT	3 (12%)	2 (8.7%)	1.00
Pre-Op BCVA	0.42 ± 0.45	0.55 ± 0.56	0.53
Pre-Op VF			0.93
Mild	5 (20%)	5 (21.7%)	
Moderate	9 (36%)	8 (34.8%)	
Advanced	11 (44%)	10 (43.5%)	

POAG, primary open-angle glaucoma; UG, uveitic glaucoma; SLT, selective laser trabeculoplasty; Pre-Op, preoperative; BCVA, best-corrected visual acuity; VF, visual field.

Performance analysis

Patients with UG and POAG had similar baseline IOPs (34.9 ± 9.4 vs. 30.0 ± 7.3 mmHg; $P = .124$) (Table 2), and a comparable number of glaucoma medications were used at baseline (3.2 ± 0.4 vs. 3.4 ± 0.5; $P = .177$). The mean IOPs and the mean number of glaucoma medications used in both groups significantly decreased from before surgery to 12 months after modified

Table 2. Mean intraocular pressure (IOP) and number of glaucoma medications taken by patients with uveitic glaucoma (UG) and primary open-angle glaucoma (POAG) after modified CLASS.

	POAG		UG		
Variable	n	%	n	%	P value
IOP (mmHg) (mean±SD)					
Preoperation	30.0 ± 7.3		34.9 ± 9.4		0.124
1 wk	8.8 ± 2.6		8.8 ± 3.0		0.637
1 mo	15.0 ± 5.5		15.5 ± 7.0		0.796
3 mo	13.4 ± 3.8		14.7 ± 5.2		0.450
6 mo	13.6 ± 2.7		14.8 ± 6.6		0.967
12 mo	14.0 ± 2.2		14.2 ± 4.2		0.796
Glaucoma medications (mean±SD)					
Preoperation	3.4 ± 0.5		3.2 ± 0.4		0.177
1 wk	0		0		1.000
1 mo	0.1 ± 0.3		0.1 ± 0.4		0.640
3 mo	0.2 ± 0.6		0.2 ± 0.6		0.900
6 mo	0.2 ± 0.5		0.7 ± 0.9		0.025
12 mo	0.4 ± 0.6		0.8 ± 1.2		0.350
Surgical outcomes (12 months)					
Qualified success	24	96	20	86.9	0.637
Complete success	16	64	14	60.9	0.859

IOP, intraocular pressure; SD, standard deviation; wk, week; mo, month.

CLASS (all $P < .001$). The mean IOPs preoperatively and at each postoperative time point are shown in Figure 2. After the initial reduction in IOP at postoperative week 1, the mean IOP increased to a peak at the first month and then gradually declined in both groups. The mean IOP reduction over time for patients with UG and POAG at every postoperative time point is presented in Table 3. At 12 months, no statistically significant differences were found in the mean IOP and mean number of glaucoma medications taken between the 2 groups. The qualified surgical success was comparable between the UG (86.9%) and POAG (96.0%) groups ($P = .637$), and the complete success rates were 60.9% and 64.0% in the UG group and POAG group, respectively ($P = .859$).

Kaplan–Meier survival curves for the 2 groups are presented in Figure 3. The BCVA ranged from 0.55 ± 0.56 preoperatively to 0.74 ± 0.73 at the last follow-up in the UG group ($P = .127$) and from 0.42 ± 0.45 to 0.29 ± 0.39 in the POAG group ($P = .001$).

Safety analyses

The overall rates of complications were similar between the 2 groups, with rates of 43.5% and 28.0% in the UG group (10 eyes) and POAG group (7 eyes), respectively ($P = .263$). Notably, 9 of 23 eyes with UG (39.1%) experienced PAS, while 7 of 25 eyes with POAG (28.0%) experienced PAS. These complications resolved after Nd:YAG laser gonioplasty, and no procedure-related complications were noted. Hyphema occurred in 1 eye with UG (4.3%), and it resolved spontaneously. The mean number of needling procedures performed was 1.43 ± 0.79 and 1.40 ± 0.55 in the UG and POAG groups, respectively, and needling was performed in 7 eyes with UG (30.4%) and 5 eyes with POAG (20.0%). LGP was performed to further enhance the aqueous drainage in 13 eyes with UG (56.5%) and 15 eyes with POAG (60.0%). The mean time between LGP and modified CLASS was 2.3 ± 1.8 months and 3.5 ± 3.7 months in the UG and POAG groups, respectively. Notably, incarceration, hypotony, bleb leaks, choroidal detachment, and infection were not observed during the 12-month follow-up.

The UBM results revealing changes in the intrascleral lake area in patients with POAG and UG are presented in Table 4. A statistically significant difference was found in the distribution of the stable group and unstable group (including mild diminution, moderate diminution, and severe diminution intrascleral lake) between 3 months and 12 months in the POAG group ($P = .046$) but not in the UG group ($P = .083$).

Discussion

In this study, the surgical outcomes of modified CLASS for patients with UG and POAG were examined. Modified CLASS appears to be an effective method for lowering IOP in patients with UG. The results indicated that this method is effective in favorably lowering IOP and reducing medication use to a similar extent in both POAG and UG eyes. In addition, the UG group and POAG group had similar overall success rates.

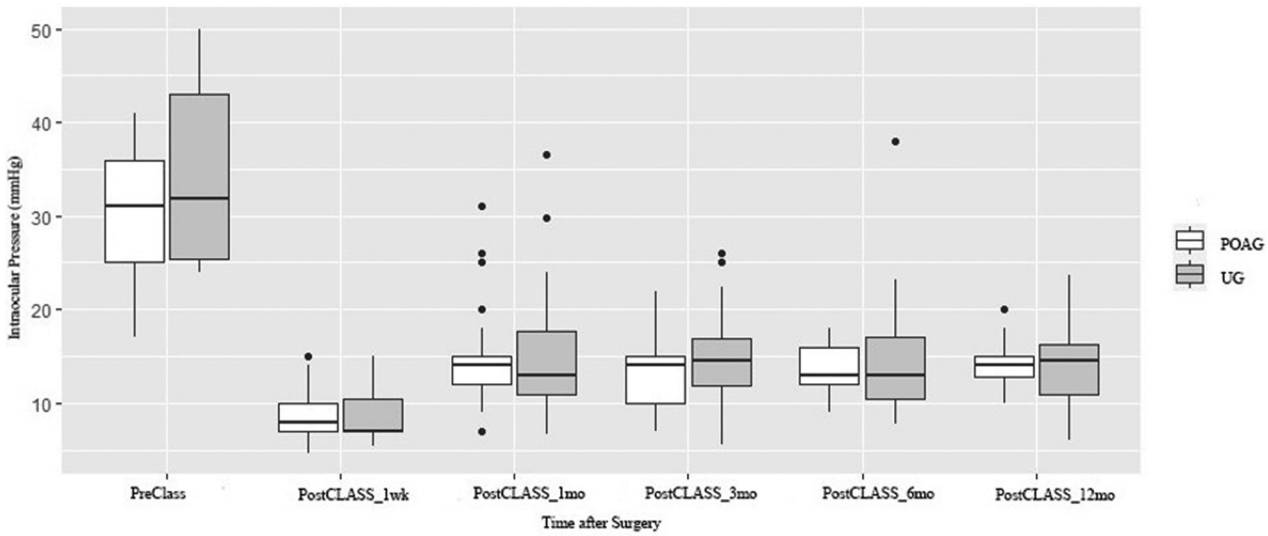

Figure 2. Comparison of the mean preoperative and postoperative intraocular pressure (IOP) in the primary open-angle glaucoma (POAG) group and uveitic glaucoma (UG) group. The central box shows the 25th to the 75th percentiles. The middle line represents the median. The vertical line extends from the minimum to the maximum. Separate circles represent outlier values (larger than the upper quartile plus three times the interquartile range).

Table 3. Reduction in the mean intraocular pressure (IOP) over time for patients with uveitic glaucoma (UG) and primary open-angle glaucoma (POAG).

		IOP (% reduction from baseline)								
Time	Group	Mean	SD	Median	Min	Max	Q1	Q3	P*	P†
After 1 week	UG	73.3	9.5	73.8	43.1	88.0	70.8	78.1	<0.0001	0.6375
	POAG	68.2	14.3	71.0	36.3	87.2	59.3	78.4	<0.0001	
After 1 month	UG	54.2	16.7	58.9	18.7	76.7	41.3	66.9	<0.0001	0.7962
	POAG	47.1	23.5	48.7	−31.6	72.7	41.7	64.4	<0.0001	
After 3 months	UG	55.3	17.9	54.3	7.0	82.4	46.7	69.6	<0.0001	0.4503
	POAG	51.8	22.2	56.5	−20.6	79.5	42.9	64.1	<0.0001	
After 6 months	UG	55.0	19.9	62.2	9.8	78.3	46.7	69.4	<0.0001	0.9670
	POAG	51.0	16.0	53.8	11.8	76.9	44.3	61.9	<0.0001	
After 12 months	UG	55.3	18.4	60.0	14.4	86.0	41.7	67.6	<0.0001	0.7958
	POAG	50.3	15.4	53.8	15.8	73.7	43.7	62.2	<0.0001	

* Intragroup analysis: Wilcoxon paired test (reductions nonnormally distributed).
† Intergroup analysis: Wilcoxon two-sample test (reductions nonnormally distributed in both groups).

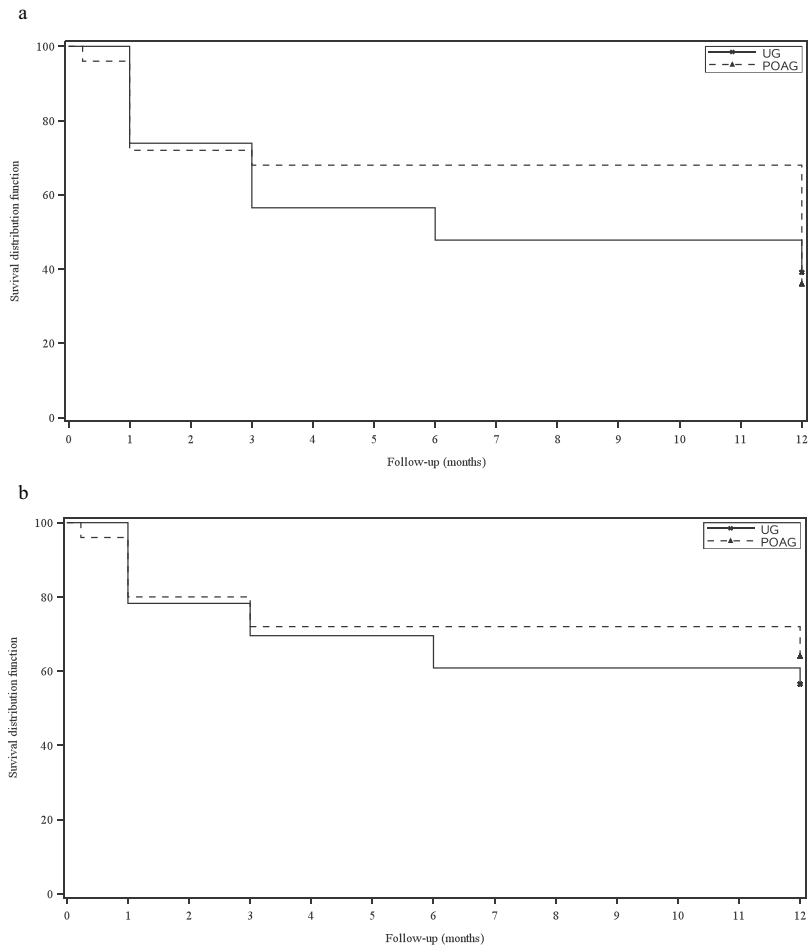

Figure 3. (a), Kaplan–Meier cumulative survival curves for the uveitic glaucoma (UG) group and primary open-angle glaucoma (POAG) group showing the complete success rates. (b), Kaplan–Meier cumulative survival curves for the UG group and POAG group showing the qualified success rates.

Table 4. UBM of the intrascleral lake at 3 months and 12 months after treatment in patients with primary open-angle glaucoma (POAG) and uveitic glaucoma (UG).

	POAG		UG	
Time point	3 months	12 months	3 months	12 months
Stable No. (%)	10 (40.0)	6 (24.0)	10 (43.48)	7 (30.43)
Mild diminution No. (%)	11 (44.0)	10 (40.0)	3 (13.04)	5 (21.74)
Moderate diminution No. (%)	2 (8.0)	7 (28.0)	10 (43.48)	7 (30.43)
Severe diminution No. (%)	2 (8.0)	2 (8.0)	0	4 (17.39)

UG is a complex group of diseases that occur at a relatively young age and directly and indirectly lead to uncontrolled high IOP, which may require more challenging treatment than POAG. Various surgical options are available to lower IOP in patients with medically uncontrolled UG. In this study, the qualified surgical success rate (86.9%) for well-controlled uveitis in patients with UG was better than that reported in previous studies using traditional trabeculectomy, suggesting that modified CLASS yields good prognoses (surgical success) in patients with UG. Iwao et al.[18] reported a 71.3% success rate for trabeculectomy with mitomycin C in 101 patients with UG, which was lower than that in patients with POAG. Kwon et al.[19] reported a qualified success rate of 67.0% for trabeculectomy in 54 patients with UG. In addition, clinical trials have reported that NPDS is an effective method for lowering IOP and has

a lower risk of complications than trabeculectomy.[20] Mercieca et al.[21] reported a success rate of 69.0% for deep sclerectomy with mitomycin C in 23 patients with UG.

However, NPDS requires a high level of surgical skill and has a steep learning curve. The goals of CLASS are to promote simpler, safer and more standardized NPDS. This improvement might be attributed to the use of a CO_2 laser, which allows for the accurate ablation of dry tissues that can then be absorbed by fluid.[22] The beam manipulator system can diminish localized heating and tissue photocoagulation and reduce coagulative thermal damage to adjacent tissues. These types of damage have been reported to cause early fibrosis, adhesion, and surgery failure.[10] Although deep ablation in classic CLASS has been reported to yield good percolation and a low IOP, it has the risk of TDM perforation, which leads to a high rate of spontaneous iris incarceration.[11] The Chinese population has a higher degree of a fibrotic response[23] and a more crowded AC than Western populations[12]; thus, the Chinese population may have a higher incidence of those complications. Therefore, continuous efforts have been focused on developing a suitable CLASS approach for Chinese patients.[24] The modified procedure in our study consists of a combination of preoperative adjuvant treatments with LPI and ALPI, a moderately enlarged scleral pool size, additional TDW zone ablation, adjustable sutures for scleral flaps and adequate perioperative anti-inflammatory treatments for patients with UG.

In detail, we first demonstrated that LPI with ALPI and pilocarpine before CLASS has a favorable therapeutic effect and largely prevented iris incarceration. Although the use of pilocarpine may increase the risk of pupil synechiae and inflammation recurrence, no obvious pilocarpine-related complications were detected in our study. Antifibrotic agents, including 5-FU, were used in all patients to delay postoperative wound healing. The long-term survival rate of trabeculectomy in patients with UG who were treated with 5-FU was reported to be comparable with that in patients with POAG.[25] Similar trends were also noted in our study.

Moreover, larger scleral flaps and deeper ablation procedures are believed to increase the level of drainage and percolation of the AH, whereas other reports have stated the opposite (i.e., that these effects are associated primarily with factors related to feasibility and the fear of penetrating the uveal tissue).[26] Our study revealed that deeper ablation might facilitate drainage of the AH to the suprachoroidal space compared with superficial surgery, thereby ensuring the patency of the scleral lake and presenting fewer cases of postoperative fibrosis. In addition, the use of a laser to perform TDW ablation increased the area for percolation and was convenient for the required LGP. Compared with studies in which non-sutured flaps were used,[27] we recommend using adjustable sutures to tightly close the scleral flap to avoid deforming the scleral lake and to prevent hypotony during the early phase of recovery. To maintain smooth outflow, we removed the sutures during the scar formation stage within 2 weeks after surgery. As expected for a nonpenetrating surgery performed to maintain a natural tissue barrier, this surgery cannot only prevent early postoperative hypotony but also limit the accumulation of inflammatory cells in the drainage area (Figure 4).

Although statistically significant differences were not observed at the 1-year follow-up visit, the qualified and complete success rates of the UG group were lower than those of the POAG group. The average number of antiglaucoma medications used and the number of needling procedures performed in the UG group were higher than those in the POAG group, suggesting that the drawback of glaucoma surgery in patients with uveitis is the risk of complications and treatment failure caused by the underlying inflammatory nature of the disease.[28] However, with a generally aggressive perioperative anti-inflammatory strategy for the UG group, the results of modified CLASS for UG seem to be comparable with those for POAG. Oral steroids began at a dose equal to 1 mg prednisone per kilogram of body weight on the day of surgery, and prednisolone acetate (1%) was given hourly 1 day

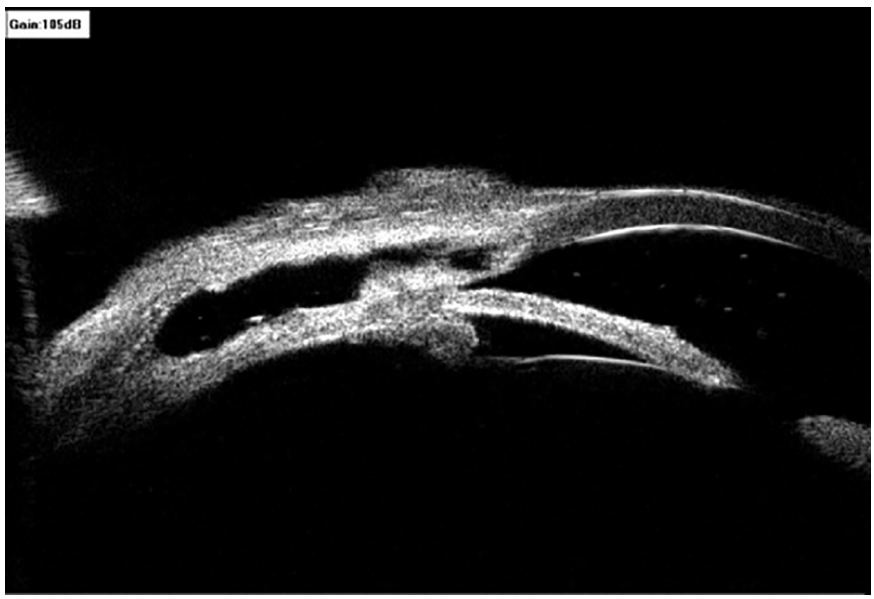

Figure 4. Compared with the intrascleral lake, the anterior chamber showed more obvious inflammatory cell infiltration.

after the operation. Then, both medications were gradually tapered based on the cellular response in the AC.

Because the number of complications did not significantly differ between patients with UG and POAG and no serious side effects were seen, modified CLASS surgery in the UG group presented here had a favorable safety profile. Visual acuity was improved in the POAG group, with a statistically significant difference observed at the 12-month follow-up: however, a declining trend was observed in the UG group. Postoperative examinations, including gonioscopy and UBM, are the most effective methods of monitoring the patency of the AH outflow channel to address changes in the channel early and improve the long-term success rate. These examinations can be used to identify the reasons for increased outflow resistance, such as fibrosis, PAS, or iris incarceration. According to the UBM results, a decreasing trend in the intrascleral lake size was found in both groups. However, no statistically significant difference was found in the distributions between the stable group and unstable group of UG eyes, indicating that the intrascleral lake was well maintained postoperatively. Based on the above improvements in the modified operation, modified CLASS seems to be an effective and feasible treatment for patients with UG, especially when considering the complex characteristics of the Chinese population.

This study is a pioneering work that used modified CLASS in patients with UG and was strengthened by the inclusion of a comparison group. Despite the novelty of our study design, it is limited by its retrospective nature, limited sample size, and follow-up period. Additional larger prospective studies with longer follow-up periods are required to assess the long-term effectiveness and safety of the modified CLASS procedure in the management of UG.

Conclusions

This study identified no significant differences in surgical success rates or complications between eyes with UG and eyes with POAG, indicating that patients with UG who undergo active perioperative anti-inflammatory therapy do not have a higher risk of surgical failure after modified CLASS than patients with POAG. The findings of this study have provided a better understanding of the risk and safety profile of CLASS in eyes with UG and suggest that modified CLASS is an appropriate surgical intervention for patients with UG.

Declaration of interest

The authors report no conflicts of interest. The authors alone are responsible for the content and writing of the paper.

ORCID

Gangwei Cheng MD http://orcid.org/0000-0001-6751-4717
Meifen Zhang MD http://orcid.org/0000-0002-7581-6800

References

1. Yeo TK, Ho SL, Lim WK, Teoh SC. Causes of visual loss associated with uveitis in a singapore tertiary eye center. *Ocul Immunol Inflamm*. 2013;21(4):264–269. doi:10.3109/09273948.2013.774424.
2. Sng CC, Barton K. Mechanism and management of angle closure in uveitis. *Curr Opin Ophthalmol*. 2015;26(2):121–127. doi:10.1097/ICU.0000000000000136.
3. Sng CC, Ang M, Barton K. Uveitis and glaucoma: new insights in the pathogenesis and treatment. *Prog Brain Res*. 2015;221:243–269.
4 Munoz-Negrete FJ, Moreno-Montanes J, Hernandez-Martinez P, Rebolleda G. Current approach in the diagnosis and management of uveitic glaucoma. *Biomed Res Int*. 2015;2015:742792. doi:10.1155/2015/742792.
5. Noble J, Derzko-Dzulynsky L, Rabinovitch T, Birt C. Outcome of trabeculectomy with intraoperative mitomycin C for uveitic glaucoma. *Can J Ophthalmol J Can D'ophtalmologie*. 2007;42(1):89–94. doi:10.3129/can.j.ophthalmol.06-124.
6. Siddique SS, Suelves AM, Baheti U, Foster CS. Glaucoma and uveitis. *Surv Ophthalmol*. 2013;58(1):1–10. doi:10.1016/j.survophthal.2012.04.006.
7. Krasnov MM. Sinusotomy in glaucoma. *Vestn Oftalmol*. 1964;77:37–41.
8. Mermoud A. Sinusotomy and deep sclerectomy. *Eye (Lond)*. 2000;14(Pt 3B):531–535. doi:10.1038/eye.2000.140.
9. Dahan E, Drusedau MU. Nonpenetrating filtration surgery for glaucoma: control by surgery only. *J Cataract Refract Surg*. 2000;26(5):695–701. doi:10.1016/S0886-3350(00)00366-7.
10. Assia EI, Rotenstreich Y, Barequet IS, Apple DJ, Rosner M, Belkin M. Experimental studies on nonpenetrating filtration surgery using the CO2 laser. *Graefes Arch Clin Exp Ophthalmol*. 2007;245(6):847–854. doi:10.1007/s00417-006-0413-4.
11. Greifner G, Roy S, Mermoud A. Results of CO2 laser-assisted deep sclerectomy as compared with conventional deep sclerectomy. *J Glaucoma*. 2016;25(7):e630–638. doi:10.1097/IJG.0000000000000187.
12. Wang D, Huang G, He M, Wu L, Lin S. Comparison of anterior ocular segment biometry features and related factors among American Caucasians, American Chinese and mainland Chinese. *Clin Exp Ophthalmol*. 2012;40(6):542–549. doi:10.1111/j.1442-9071.2011.02746.x.
13. Ho CL, Walton DS. Goniosurgery for glaucoma secondary to chronic anterior uveitis: prognostic factors and surgical technique. *J Glaucoma*. 2004;13(6):445–449. doi:10.1097/01.ijg.0000141368.96950.3c.
14. Pereiro X, Ruzafa N, Acera A, Fonollosa A, Rodriguez FD, Vecino E. Dexamethasone protects retinal ganglion cells but not Müller glia against hyperglycemia in vitro. *PloS One*. 2018;13(11):e0207913. doi:10.1371/journal.pone.0207913.
15. Heiduschka P, Thanos S. Cortisol promotes survival and regeneration of axotomised retinal ganglion cells and enhances effects of aurintricarboxylic acid. *Graefes Arch Clin Exp Ophthalmol*. 2006;244(11):1512–1521. doi:10.1007/s00417-005-0164-7.
16. Shaarawy T, Nguyen C, Schnyder C, Mermoud A. Comparative study between deep sclerectomy with and without collagen implant: long term follow up. *Br J Ophthalmol*. 2004;88(1):95–98. doi:10.1136/bjo.88.1.95.
17. Bissig A, Rivier D, Zaninetti M, Shaarawy T, Mermoud A, Roy S. Ten years follow-up after deep sclerectomy with collagen implant. *J Glaucoma*. 2008;17(8):680–686. doi:10.1097/IJG.0b013e318182ed9e.
18. Iwao K, Inatani M, Seto T, et al. Long-term outcomes and prognostic factors for trabeculectomy with mitomycin C in eyes with uveitic glaucoma: a retrospective cohort study. *J Glaucoma*. 2014;23(2):88–94. doi:10.1097/IJG.0b013e3182685167.
19. Kwon HJ, Kong YXG, Tao LW, et al. Surgical outcomes of trabeculectomy and glaucoma drainage implant for uveitic glaucoma and relationship with uveitis activity. *Clin Exp Ophthalmol*. 2017;45(5):472–480. doi:10.1111/ceo.12916.
20. Hondur A, Onol M, Hasanreisoglu B. Nonpenetrating glaucoma surgery: meta-analysis of recent results. *J Glaucoma*. 2008;17(2):139–146. doi:10.1097/IJG.0b013e31814b98f7.
21. Mercieca K, Steeples L, Anand N. Deep sclerectomy for uveitic glaucoma: long-term outcomes. *Eye (Lond)*. 2017;31(7):1008–1019. doi:10.1038/eye.2017.80.

22. Geffen N, Ton Y, Degani J, Assia EI. CO2 laser-assisted sclerectomy surgery, part II: multicenter clinical preliminary study. *J Glaucoma*. 2012;21(3):193–198. doi:10.1097/IJG.0b013e3181f7b14f.
23. Wang Y, Sun XH, Meng FR, Wang JJ. The failure causes of non-penetrating trabecular surgery and reoperation. *Zhonghua Yan Ke Za Zhi*. 2003;39:87–90.
24. Zhang Y, Cheng G. Modified CO2 laser-assisted sclerectomy surgery in chinese patients with primary open-angle glaucoma and pseudoexfoliative glaucoma: a two-year follow-up study. *J Glaucoma*. 2020;29:367–373. doi:10.1097/IJG.0000000000001460.
25. Chawla A, Mercieca K, Fenerty C, Jones NP. Outcomes and complications of trabeculectomy enhanced with 5-fluorouracil in adults with glaucoma secondary to uveitis. *J Glaucoma*. 2013;22(8):663–666. doi:10.1097/IJG.0b013e318255dc07.
26. Jankowska-Szmul J, Dobrowolski D, Wylegala E. CO2 laser-assisted sclerectomy surgery compared with trabeculectomy in primary open-angle glaucoma and exfoliative glaucoma. A 1-year follow-up. *Acta Ophthalmol*. 2018. doi:10.1111/aos.13718.
27. Yick DW, Lee JW, Tsang S, Yeung BY, Yuen CY. Preliminary results of CO2 laser-assisted sclerectomy surgery (CLASS) in the treatment of advanced glaucoma in a Chinese population. *Medicine (Baltimore)*. 2016;95(45):e5294. doi:10.1097/MD.0000000000005294.
28. Shimizu A, Maruyama K, Yokoyama Y, Tsuda S, Ryu M, Nakazawa T. Characteristics of uveitic glaucoma and evaluation of its surgical treatment. *Clin Ophthalmol*. 2014;8:2383–2389. doi:10.2147/OPTH.S72383.