



NEW YORK
HEAD & NECK
INSTITUTE

Palatal stiffening via transoral, retrograde interstitial laser coagulation

Yosef P. Krespi MD, Victor Kizhner MD

ABSTRACT

Introduction:

Current treatment modalities for snoring include minimally invasive procedures which may include mucosal removal, coblation or radiofrequency palatoplasty, injection snoreplasty and placement of palatal implants. Disadvantages include high cost, postoperative pain, occasional mucosal slough and implant extrusion. We introduce a new laser assisted method avoiding intraoral injury.

Methods:

A pilot study with ten loud snorers and RDI<8 were treated. A 980nm diode laser with 300micron fiber and special handle with curved needle was used. Under local anesthesia the fiber was introduced into the nasal surface of soft palate between palatoglossal and glossopharyngeal arches and advanced progressively anteriorly after pulling the uvula forward. The method included three retrograde fiber passes penetrating nasopharyngeal mucosa of the soft palate. One central and two lateral interstitial laser fiber passes at 9W for average 20sec was used to create palatal scarring and stiffening.

Results:

All patients responded to a phone survey one month after the procedure. Four patients reported significant improvement, 3 had some improvement, 2 had mild improvement and one patient had no change. Pain score was moderate for 3 patients while the rest had mild pain.

Conclusions:

We report encouraging results of this small series. The excellent wavelength absorption makes it ideal for tissue modulating without significant bleeding. We find it advantageous for the following reasons: inexpensive, reproducible results, minimal postoperative discomfort, can be energy titrated, pain is minimal, has possible favorable oral intake due to minimal interference with food passage, safe office procedure and patient appealing. Those results encourage further studies.

CONTACT

Name: Yosef Krespi, M.D.
Organization: St. Luke's Roosevelt Hospital
Email: hnsq@aol.com
Phone: 212-262-4444
Website: www.nyhni.org

INTRODUCTION

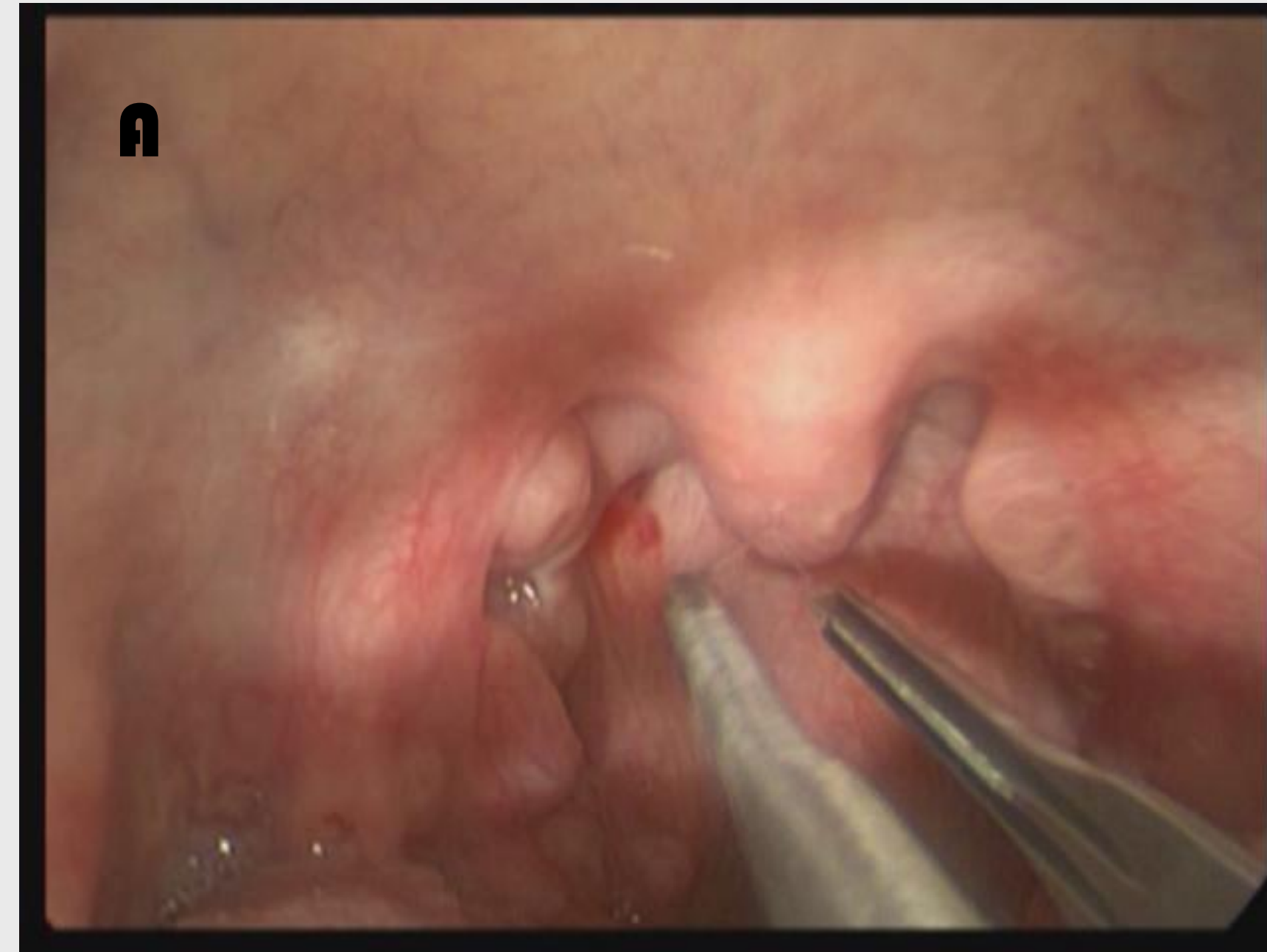Snoring affects as high as 20% of the population and may impact to breathing during sleep. Surgical and non surgical treatment options for snoring have soared in the past years especially with the advent of minimally invasive office procedures such as laser palatoplasty, radiofrequency (RF) volumetric reduction, the Pillar procedure and increase use oral appliances. Uvulo-palatopharyngoplasty, usually performed under general anesthesia will eliminate snoring with a significant amount of post-operative pain and is usually considered "overkill" in the absence of OSA. Laser assisted uvulo-palatoplasty (LAUP) can be performed under local anesthesia in the office, also resulting in significant postoperative discomfort. The patient expectations from an elective snoring therapy without the presence of OSA are very high. Patient satisfaction is greatest with an effective, rapid in-office procedure with minimal post surgical down time at a reasonable cost. Energy deliverance by -an ablative mode using lasers or RF attempts to reduce excessive palatal volume with further scar formation, results in intrapalatal stiffening. RF has its drawbacks such as cost for disposables, the need for occasional repeated procedure due to absence of standardization, lack of uvular management, complications (i.e., erosion and ulceration). A recent study suggests (contrary to previous short term results) that radiofrequency may be redundant for a long term desired effect.

Energy deliverance by laser can achieve similar results and also being cost effective. Lasers are commonly found in ENT office practice used for wide range of applications. A 980nm near-infra-range (NIR) diode laser (Lumenis, Santa Clara, CA) is a small, economical, battery operated with a flexible fiber that can be attached to a hand-piece with curved needle tip. Energy deliverance at 7-8 watts is used in continuous mode in contact or interstitially by penetrating into the palatal muscles.

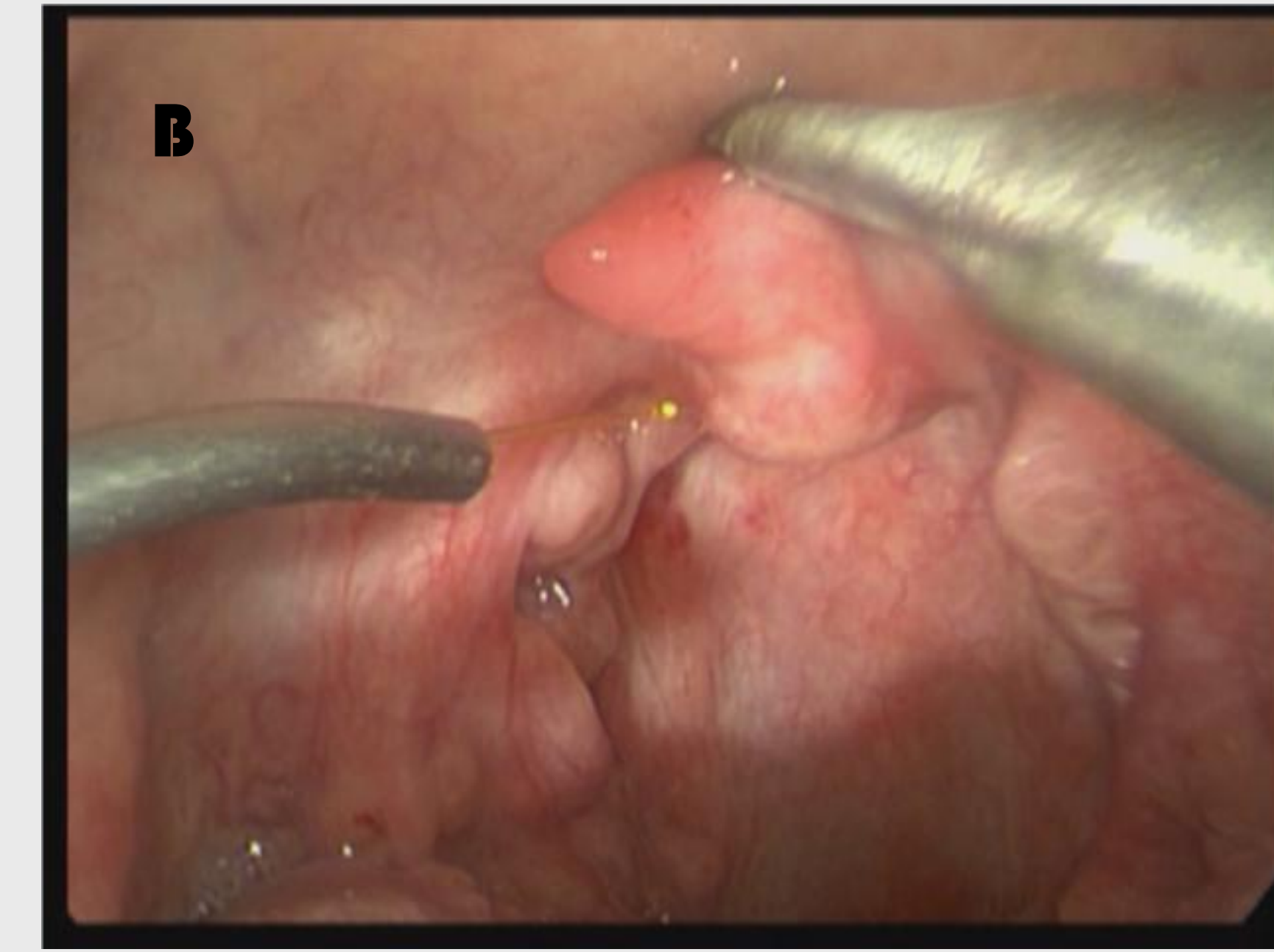
We are presenting a new, minimally invasive, effective method for snoring cessation with a 980nm NIR diode laser by targeting the nasal surface of the uvula and soft palate. One of the limitations of the previous surgical procedures is significant discomfort and swelling that will affect oral intake. By avoiding injury to the oral mucosa traversing and targeting the palatal muscles from its nasal surface we have avoided injury to oral mucosa and eliminated postoperative discomfort associated with deglutition.

METHODS AND MATERIALS

Following injection of local anesthesia to the center soft palate in an office ENT chair, a 980nm NIR laser with 300micron fiber coupled to a surgical hand-piece and curved needle tip was used. Laser settings were 7-8W in continuous mode. Ten otherwise healthy snorers with AHI<10 and no other co morbidities were treated in the office. The tip of the uvula was grasped gently with forceps and flipped anteriorly. The laser fiber was inserted penetrating the nasal surface of palatal mucosa around the base of the uvula and advanced further anteriorly into the soft palate muscles. At least three passes were made (one center and two lateral) for about 10 seconds. The laser fiber was advanced in a retrograde fashion about 2-3cm from the base of the uvula in the midline and two additional lateral passes were made. Total energy deliverance was no more than 1000J. The patients filled a 0-10VAS questionnaire where 0 is no snoring and 10 represents very loud and disturbing snoring. Results before and one month after the procedure were recorded. Complications if arose were noted. Pain intensity was collected based on scale comprised of mild / moderate or severe for simplification.



A- The uvula is flipped upwards

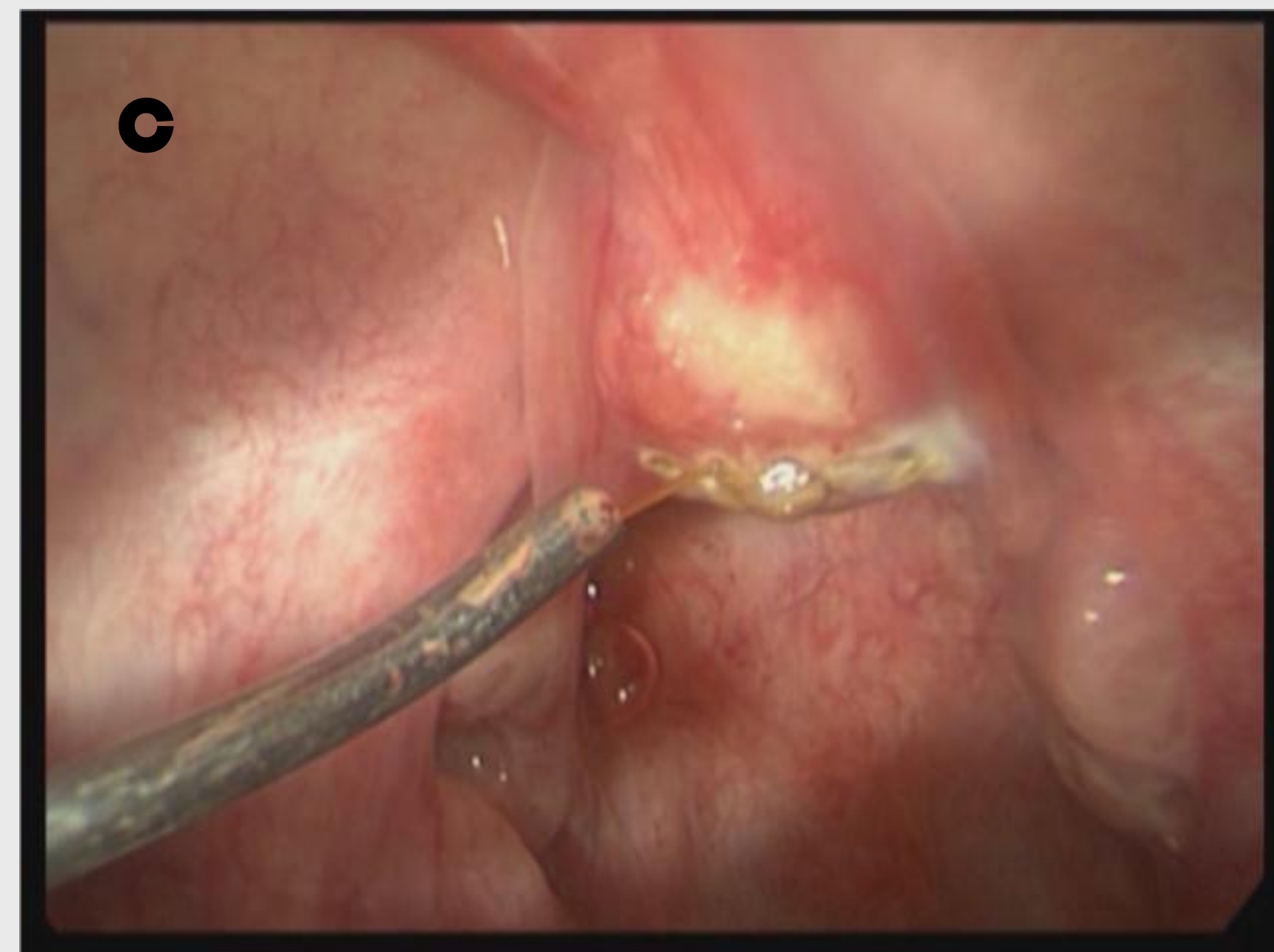


B-The laser is about to be introduced retrogradely in the flipped uvula

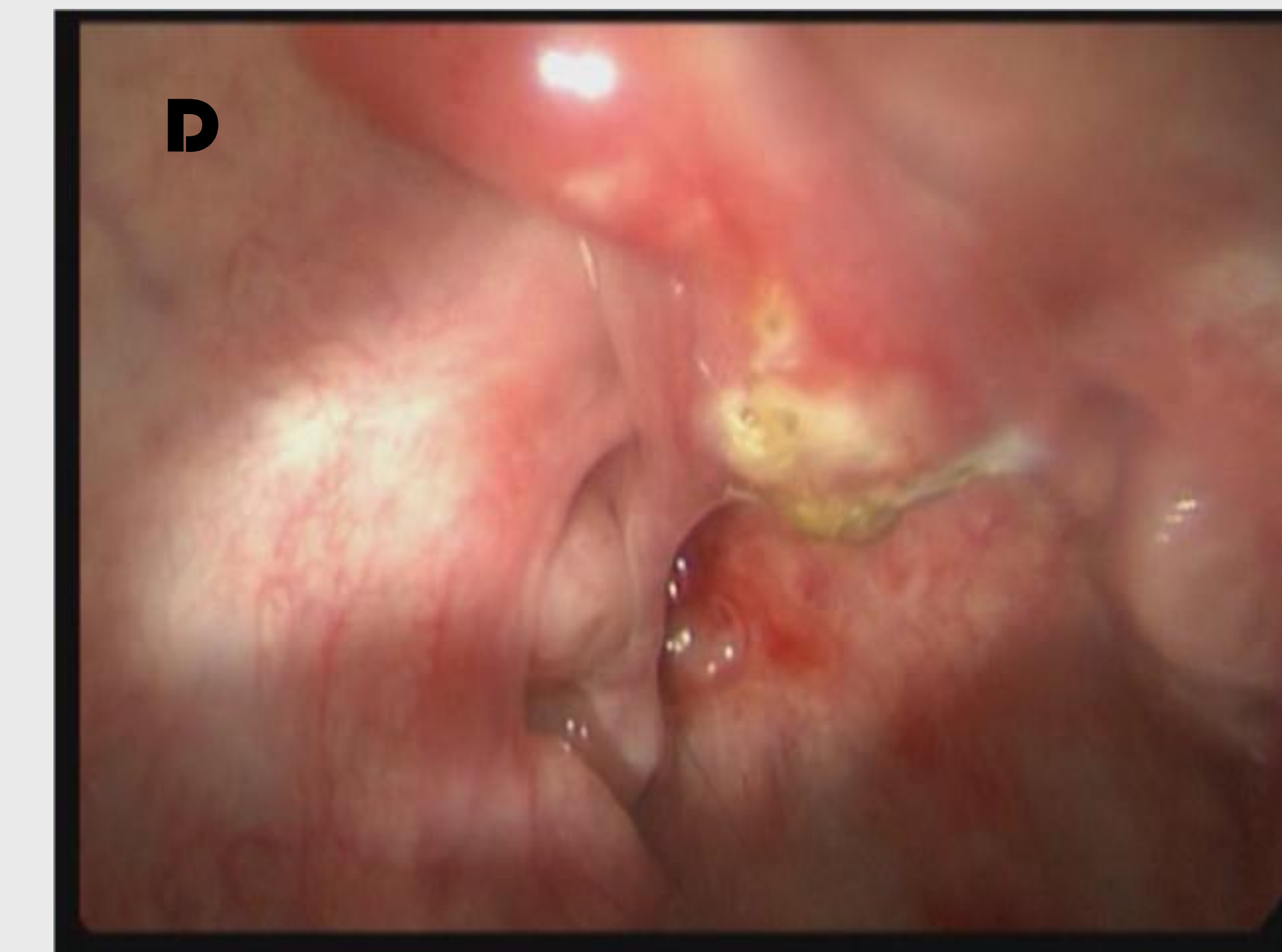
RESULTS

All patients responded to a phone survey one month after the procedure. Four patients reported significant improvement, 3 had some improvement, 2 had mild improvement and one patient had no change. Pain score was moderate for 3 patients while the rest had mild pain.

C- Retrograde interstitial laser ablation on pharyngeal side



D- The result in the end



DISCUSSION

We conducted a pilot study examining a new potential treatment for simple snoring without OSA. Our method is innovative by its retrograde technique and by keeping the oral mucosa intact. This is reflected in a posterior to anterior interstitial passage of the laser fiber. Our goal was to avoid damage or injury to oral mucosa, allowing better oral intake, reduce postoperative pain and avoiding possible wound contamination. This method addresses palatal snoring via interstitial retrograde palatal laser stiffening. The laser achieves precise energy deliverance with an easy to use ergonomic hand-piece design. The laser wavelength combined with heat is ideal for interstitial coagulation resulting in stiffening. The lack of complications speculatively can be attributed to the laser's disinfectant properties.

Patient satisfaction was high as their oral and pharyngeal pain was minimal and did not interfere with oral intake. Surgical time was short and done under local anesthesia in the office enabling quick recovery. As the proximal part of the fiber can be resterilized and reused, cost effectiveness is maintained.

This pilot study has several limitations. The follow up is short and our cohort small. Exact energy may be optimized better. Nevertheless a postero-anterior transnasal mucosa based interstitial ablation of the center compartment of soft palate performed in the office defines most of the factors qualifying for the ideal snoring treatment method.

CONCLUSIONS

We report encouraging results of this small series. The excellent wavelength absorption makes it ideal for tissue modulating without significant bleeding. We find it advantageous for the following reasons: inexpensive, reproducible results, minimal postoperative discomfort, can be energy titrated, pain is minimal, has possible favorable oral intake due to minimal interference with food passage, safe office procedure and patient appealing. Those results encourage further studies

REFERENCES

Radiofrequency-assisted uvulopalatoplasty for snoring: Long-term follow-up. Stuck BA. Laryngoscope. 2009 Aug;119(8):1617-20.
Radiofrequency ablation treatment of soft palate for patients with snoring: a systematic review of effectiveness and adverse effects. Bäck LJ, Hytönen ML, Roine RP, Malmivaara AO. Laryngoscope. 2009 Jun;119(6):1241-50.