

## Motor Evoked Potentials for Femoral Nerve Protection in Transpsoas Lateral Access Surgery of the Spine

Jon Block, D.C., CNIM<sup>1</sup>; Justin W. Silverstein, DHSc, CNIM, R. EP T. R.NCS.T., CNCT, NCT-C<sup>2,3</sup>; Hieu T. Ball, M.D.<sup>4</sup>; Laurence E. Mermelstein, M.D.<sup>5</sup>; Hargovind S. DeWal, M.D.<sup>5</sup>; Rick Madhok, M.D.<sup>6</sup>; Sushil K. Basra, M.D.<sup>5</sup>; Matthew J. Goldstein, M.D.<sup>7</sup>

<sup>1</sup>*ION Intraoperative Neurophysiology, LLC  
Walnut Creek, California*

<sup>2</sup>*Neuro Protective Solutions, LLC  
Commack, New York*

<sup>3</sup>*Spine Medical Services, PLLC  
Commack, New York*

<sup>4</sup>*California Comprehensive Spine Institute, Inc.  
San Ramon, California*

<sup>5</sup>*Long Island Spine Specialists, PC  
Commack, New York*

<sup>6</sup>*Neuroaxis Neurosurgical Associates, PC  
Kew Gardens, New York*

<sup>7</sup>*Orthopedic Associates of Manhasset, PC  
Great Neck, New York*

**ABSTRACT.** *Detecting potential intraoperative injuries to the femoral nerve should be the main goal of neuromonitoring of lateral lumbar interbody fusion (LLIF) procedures. We propose a theory and technique to utilize motor evoked potentials (MEPs) to protect the femoral nerve (a peripheral nerve), which is at risk in LLIF procedures. MEPs have been advocated and widely used for monitoring spinal cord function during surgical correction of spinal deformity and surgery of the cervical and thoracic spine, but have had limited acceptance for use in lumbar procedures. This is due to the theoretical possibility that MEP recordings may not be sensitive in detecting an injury to a single nerve root considering there is overlapping muscle innervation of adjacent root levels. However, in LLIF*

Corresponding Author's Email: [wiredneuro@gmail.com](mailto:wiredneuro@gmail.com)

Received: September 16, 2014. Accepted for publication: November 21, 2014.

Color versions of one or more of the figures in the article can be found online at [www.tandfonline.com/utnj](http://www.tandfonline.com/utnj).

*procedures, the surgeon is more likely to encounter lumbar plexus elements than nerve roots. Within the substance of the psoas muscle, the L2, L3, and L4 nerve roots combine in the lumbar plexus to form the trunk of the femoral nerve. At the point where the nerve roots become the trunk of the femoral nerve, there is no longer any alternative overlapping innervation to the quadriceps muscles. Insult to the fully formed femoral nerve, which completely blocks conduction in motor axons, should theoretically abolish all MEP responses to the quadriceps muscles. On multiple occasions over the past year, our neuro-monitoring groups have observed significantly degraded amplitudes of the femoral motor and/or sensory evoked potentials limited to only the surgical side. Most of these degraded response amplitudes rapidly returned to baseline values with a surgical intervention (i.e., prompt removal of surgical retraction).*

**KEY WORDS.** *Femoral nerve, intraoperative monitoring, lateral lumbar interbody fusion, motor evoked potentials, somatosensory evoked potentials, transpsoas lateral access to the spine.*

## INTRODUCTION

Transcranial motor evoked potentials (MEPs) have been widely advocated and utilized for monitoring spinal cord function during surgical correction of spinal deformity and surgery of the cervical spine. MEPs can provide surgeons with a useful near-real-time functional assessment of the spinal motor pathways throughout a surgical procedure (Li et al. 2012, Lall et al. 2012, Clark et al. 2013). MEPs have had more limited acceptance for use in lumbar procedures due to the theoretical possibility that MEP recordings may not be sensitive in detecting an injury to a single nerve root considering there is overlapping muscle innervation of adjacent root levels (Jahangiri 2013, Lyon et al. 2010, Lyon et al. 2009a, Lyon et al. 2009b, Mok et al. 2008). This drawback of MEP monitoring for nerve root protection may not apply to MEP monitoring aimed at protecting more distal neural elements such as the fully formed peripheral nerves. We propose a theory and technique to utilize MEPs to protect the femoral nerve (a peripheral nerve), which is at risk in transpsoas lateral lumbar interbody fusion (LLIF) procedures (Block and Silverstein 2014).

We will summarize our rationale for the utilization of MEPs and share our initial observations from our first year of using a multimodal approach for femoral nerve protection in LLIF procedures, including MEPs, saphenous nerve somatosensory evoked potentials (SSEPs), and electromyography (EMG).

### Relevant Anatomy and Theory

It is essential to have a clear understanding of the lumbar plexus anatomy in order to monitor LLIF procedures effectively. In this procedure, surgeons are less

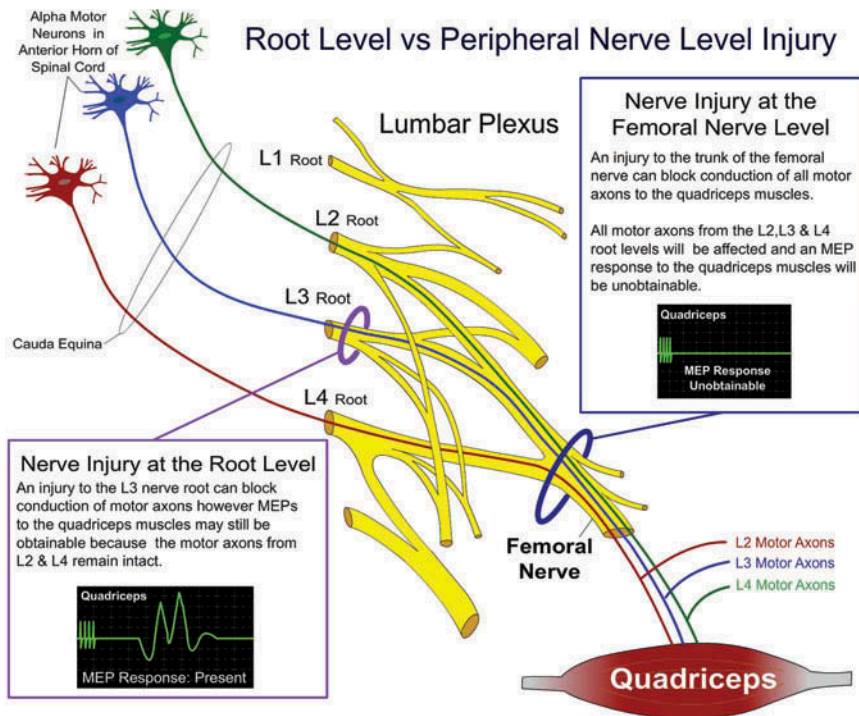
likely to encounter the nerve roots directly than they would be in a transforaminal lumbar interbody fusion (TLIF) or posterior lumbar interbody fusion (PLIF) procedure, and they are more likely to encounter the lumbar plexus elements, including the trunk of the femoral nerve. Femoral nerve contributions and even the fully formed trunk are particularly at risk when the retractor blades are opened (especially at L4-5) (Davis et al. 2011). This has important clinical implications, as well as implications for how the procedure can be monitored adequately.

### **Rationale for MEP Monitoring**

Within the substance of the psoas muscle, the L2, L3, and L4 nerve roots combine to form the trunk of the femoral nerve. At the point where the nerve roots become the trunk of the femoral nerve, there is no longer any alternative overlapping innervation to the quadriceps muscles. Thus, a focal insult to the fully formed femoral nerve, which completely blocks conduction in motor axons, should theoretically abolish all MEP responses recorded from the quadriceps muscles. In LLIF procedures, it is suspected that excessive tissue retraction on the psoas muscle stretches or compresses the components of the femoral nerve or related vasculature. Isolated femoral nerve injuries have been well described in the literature (Ahmadian et al. 2013, Houten et al. 2011, Lykissas et al. 2014, Rodgers et al. 2011, Sofianos et al. 2012). It is important to make the distinction that these are not nerve root injuries, which are commonly associated with lumbar spine surgery. Surgeons and neurophysiologists should appreciate the devastating effects of a high-grade femoral nerve injury, which can be significantly more debilitating than a nerve root injury. For example, a complete injury to the L3 nerve root may result in paresis (weakness) of the quadriceps muscles, as the patient may retain some functional knee extension from the intact L2 and L4 nerve root contributions to the quadriceps muscles. In contrast, a complete femoral nerve injury would affect all motor fibers from all root contributions (L2, L3, and L4), and the patient's quadriceps would be paralyzed, with no ability to extend the knee (Figure 1). This example illustrates why femoral nerve injuries are the most feared neurological complications of LLIF procedures and femoral nerve protection should be the highest priority for any LLIF neuromonitoring protocol.

### **Theory for the Utility of MEPs for LLIFs, and Rationale for Intervention**

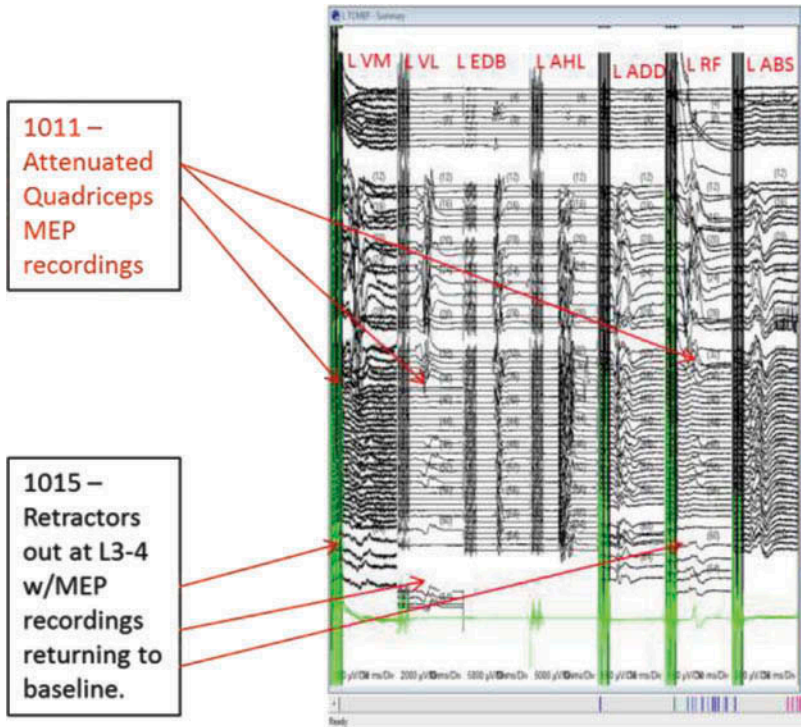
The suspected mechanism of femoral nerve injury in LLIF procedures is excessive surgical retraction, which results in stretch or compression affecting the trunk of the femoral nerve. Excessive retraction can lead to conduction block of the femoral nerve. At this point, we would theoretically expect to see a significant degradation of the MEP response amplitude limited to the surgical-side quadriceps muscles. All other MEP



**FIG. 1.** This illustration shows the theoretical effects of a complete nerve root injury compared to a complete femoral nerve injury along with the expected effects on the motor evoked responses to the quadriceps muscles in each scenario. MEP responses may still be present despite a complete injury to the L3 nerve root, as collateral innervation from the intact L2 and L4 roots will continue to transmit nerve impulses to the quadriceps muscles. In contrast, complete injury to the trunk of the femoral nerve will eliminate all motor conduction from the L2, L3, and L4 root contributions to the femoral nerve, and MEPs will be unobtainable. *Picture courtesy of Jon Block, DC, CNIM.*

recordings from distal muscles as well as the contralateral (nonsurgical-side) quadriceps MEP response amplitude should theoretically remain unchanged (Figures 2A and 2B).

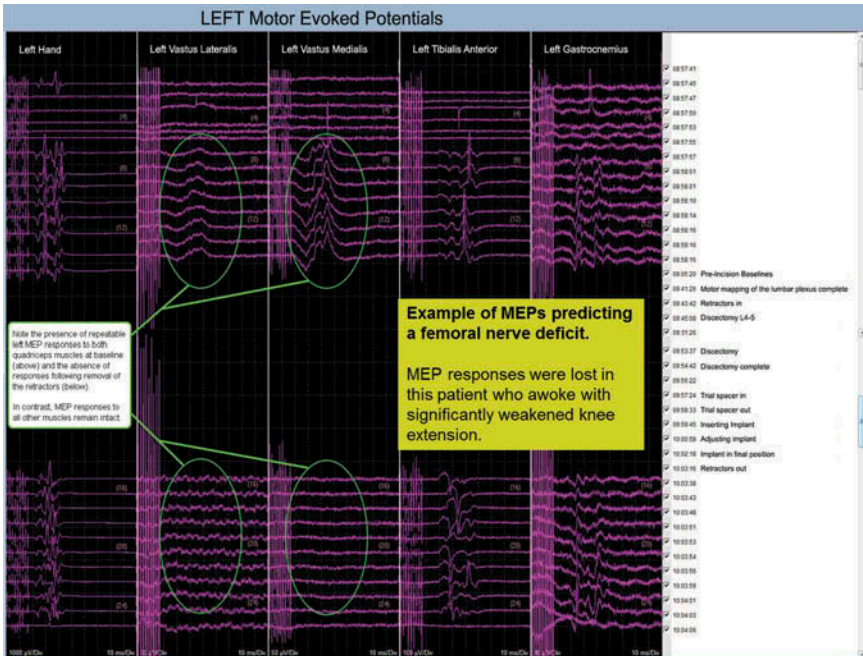
There have been multiple animal studies where peripheral nerve conduction is recorded while stretch or compressive forces are applied to a peripheral nerve segment (Kiernan and Kaji, 2013, Li and Shi 2007, Ochs et al. 2000). It has been demonstrated that with increasing forces applied over time, at some point, nerve conduction ceases and impulses are no longer conducted across the stretched or compressed segment (conduction block). These studies also illustrate that peripheral nerves are resilient, so that if the offending stretch or compression does not structurally damage the nerve and is discontinued in a timely manner, nerve function tends to return rapidly. These studies have also illustrated that prolonged or excessive stretch or compression on peripheral



**FIG. 2A.** Approach-side attenuation of quadriceps MEPs (VM, VL, and RF). Ipsilateral AHL, abdominals, and adductors remained unchanged. This occurred during the placement of the arthrodesis at the L2-L3 level. We hypothesize that retraction of the psoas muscle causing compression of the femoral nerve or significant contributions to the femoral nerve caused the change at the L2-L3 level. Another theory is that the patient may have had a prefixed lumbar plexus, making the formation of the femoral nerve aberrant. (L: left, VM: vastus medialis, VL: vastus lateralis, EDB: extensor digitorum brevis, AHL: abductor hallucis longus, ADD: adductors, RF: rectus femoris, ABS: abdominals). *Picture courtesy of Justin Silverstein, DHSc, CNIM.*

nerves can lead to irreversible damage (Kiernan and Kaji, 2013, Li and Shi, 2007, Ochs et al. 2000).

The key to neuromonitoring for femoral nerve protection in LLIF procedures is to identify and report the point at which femoral nerve conduction begins to fail. Prompt countermeasures to remove the offending retraction should theoretically result in a rapid return of function that should correlate with a return of femoral nerve evoked potentials response amplitude (Figure 3). The ability to alert the surgeon to a change in the functional status of the femoral nerve is a powerful tool that can help to prevent excessive surgical retraction from causing irreversible damage to the femoral nerve. Detecting temporary, reversible conduction block



**FIG. 2B.** Approach-side loss of quadriceps MEPs (vastus lateralis and vastus medialis). Note the presence of repeatable left MEP responses to both quadriceps muscles at baseline and the absence of responses following removal of the retractors. This occurred while the surgeon was working on the L4-L5 level. *Picture courtesy of Justin Silverstein, DHS, CNIM.*

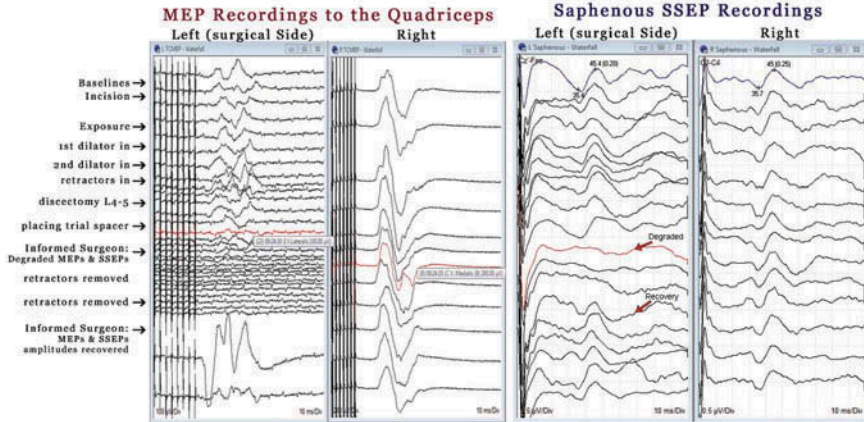
affecting the femoral nerve should be the primary objective of neuromonitoring of LLIF procedures (especially at L4-5).

### Multimodality Neuromonitoring for Femoral Nerve Protection

Over the last year, we have employed a multimodality approach to monitoring femoral nerve function during LLIF procedures; this approach utilizes information obtained from MEP recordings of the quadriceps muscles in conjunction with information from saphenous nerve SSEPs (Silverstein et al. 2014). We believe this multimodality approach provides the surgeon with a comprehensive intraoperative assessment of femoral nerve function throughout the procedure. Surgeons should appreciate that a functional assessment of the femoral nerve cannot be obtained with triggered EMG using an electrical probe or by stimulating with electrodes that are placed on retractor blades due to the distinct possibility of false negative responses. Even in the instance of a fully transected nerve, electrical stimulation within the

**CASE STUDY:**

Unilateral, temporary loss of the MEP responses to the surgical side quadriceps that correlated with a unilateral loss of the surgical side Saphenous SSEPs which recovered rapidly after removal of surgical retraction. Note the contralateral quadriceps MEPs and contralateral Saphenous SSEPs remained unchanged.



**FIG. 3.** Unilateral, temporary loss of the MEP responses to the surgical-side quadriceps that correlated with a unilateral loss of the surgical-side saphenous SSEP, which recovered rapidly after the removal of surgical retraction. Note the contralateral quadriceps MEPs and contralateral saphenous SSEP remained unchanged. This was during work on the L4-L5 level. *Picture courtesy of Jon Block, DC, CNIM.*

surgical field can continue to elicit motor responses in the distal transected nerve segment, which may remain electrically excitable for up to 72 hours (Lubińska 1977, Beirowski et al. 2005). Continuous recording of spontaneous EMG has been widely advocated for LLIFs (Ozgun et al. 2006, Tohmeh et al. 2011). However, using spontaneous EMG has recently been questioned in the literature with regards to its usefulness in detecting certain mechanisms of neural injury such as slow stretch/compression and/or ischemia, which are more likely to be culpable in LLIFs (Duncan et al. 2012, Silverstein et al. 2014).

## METHODS

The most valuable MEP information is obtained from surgical-side quadriceps muscle recordings. MEPs are elicited in standard fashion with anodal stimulation applied to the scalp using an M3/4- M4/3 montage, using between 5 and 9 pulses with an interstimulus interval range between 2 ms and 4 ms and the minimum voltage required to elicit optimal quadriceps responses (MacDonald et al. 2013). It is important for the neurophysiologist to adjust the stimulation parameters with the goal of optimizing the quadriceps muscle responses. Consistent, repeatable MEP responses can be more difficult to obtain in proximal muscle recordings such as the quadriceps because

of their limited representation in corticospinal tracts (Houten et al. 2011, Siegel and Sapru 2010). We recommend recording using needle electrodes from a minimum of two quadriceps muscles (e.g., rectus femoris and vastus medialis) to increase the chances of obtaining useful recordings and to reduce the effects of sampling error. Contralateral quadriceps MEP recordings are useful as a comparison control and helpful in the interpretation of any changes. In our experience, there is considerable variability from patient to patient in the quality and utility of the femoral motor and sensory evoked potential recordings.

The consistency of MEP responses to the quadriceps muscles varies and there are multiple factors that must be considered that can affect the quality of the MEP recordings. Similarly, variability in the saphenous SSEP responses is not uncommon. Because of this patient-to-patient variability, the neurophysiologist must adequately describe the quality of baseline evoked potential recordings to the surgeon so that he or she is aware of the diagnostic utility of the neuromonitoring for that particular patient. In most patients, we have been able to obtain either a repeatable saphenous SSEP recording and/or a repeatable quadriceps MEP response on the surgical side. Having redundant information (motor and sensory) on femoral nerve function is helpful because of the variability of response quality in the two modalities and the potential of not obtaining useful recordings in one of the modalities at baseline. It should be understood that it is possible that neither modality will yield repeatable, useful baseline recordings and therefore that a functional assessment of the femoral nerve will not be available during the procedure. However, in most cases we have been able to obtain good-quality, repeatable evoked potential recordings at baseline in at least one of the modalities and many times in both. Neuromonitoring for femoral nerve protection in LLIFs is somewhat more technically challenging than traditional spinal cord monitoring, and our neuromonitoring groups have noticed an improved rate of obtaining useful baseline recordings with time and practice.

Limitations have to be considered when adding MEPs to the monitoring paradigm of LLIFs. Total intravenous anesthesia (TIVA) is suggested for optimal multimodal monitoring. Short-acting paralytics (e.g., succinylcholine) may be used at induction, and all paralytics should be avoided thereafter. Inhalational agents will have a dose-dependent suppressive effect on the MEP and SSEP response amplitudes and may add complexity to the interpretation of changes. An anesthesia protocol utilizing TIVA is highly recommended.

## CONCLUSION

Over the last year, on multiple occasions, our neuromonitoring groups have observed unilateral (surgical-side-only) degraded amplitudes of the femoral motor and/or sensory evoked potentials, many of which resolved with a surgical intervention (i.e., prompt removal of surgical retraction). Our initial observations appear promising



and suggest that MEPs may be an important part of a multimodal neuromonitoring paradigm, in conjunction with saphenous SSEPs and EMG, to monitor for femoral nerve protection in LLIF procedures. Though these initial findings are compelling, more study is needed to better assess the utility of these techniques.

## REFERENCES

- Ahmadian A, Deukmedjian AR, Abel N, Dakwar E, Uribe JS. Analysis of lumbar plexopathies and nerve injury after lateral retroperitoneal transpsoas approach: Diagnostic standardization. *J Neurosurg Spine* 2013; 18(3):289–97.
- Beirowski B, Adalbert R, Wagner D, Grumme DS, Addicks K, Ribchester RR, Coleman MP. The progressive nature of Wallerian degeneration in wild-type and slow Wallerian degeneration (Wlds) nerves. *BMC Neurosci* 2005; 6:6.
- Block J, Silverstein J. The utility of transcranial motor evoked potentials (MEPs) for intraoperative monitoring of femoral nerve function for retroperitoneal transpsoas access to the spine. ASET -The Neurodiagnostic Society Annual Conference, Asheville, NC, August 2014.
- Clark AJ, Ziewacz JE, Safaei M, Lau D, Lyon R, Chou D, Weinstein PR, Ames CP, Clark, JP 3<sup>rd</sup>, Mummaneni PV. Intraoperative neuromonitoring with MEPs and prediction of postoperative neurological deficits in patients undergoing surgery for cervical and cervicothoracic myelopathy. *Neurosurgical Focus* 2013; 35(1):E7.
- Davis TT, Bae HW, Mok JM, Rasouli A, Delamarter RB. Lumbar plexus anatomy within the psoas muscle: Implications for the transpsoas lateral approach to the L4-L5 disc. *J Bone Joint Surg Am* 2011; 93(16):1482–7.
- Duncan JW, Bailey RA, Baena R. Intraoperative decrease in amplitude of somatosensory-evoked potentials of the lower extremities with interbody fusion cage placement during lumbar fusion surgery. *Spine (Phila Pa 1976)* 2012; 37(20):E1290–5.
- Houten JK, Alexandre LC, Nasser R, Wollowick AL. Nerve injury during the transpsoas approach for lumbar fusion. *J Neurosurg Spine* 2011; 15(3):280–4.
- Jahangiri FR. Multimodality neurophysiological monitoring during tibial/fibular osteotomies for preventing peripheral nerve injuries. *Neurodiagn J* 2013; 53(2):153–68.
- Kiernan MC, Kaji R. Physiology and pathophysiology of myelinated nerve fibers. *Handb Clin Neurol* 2013; 115:43–54.
- Lall RR, Lall RR., Hauptman JS, Munoz C, Cybulski GR, Koski T, Ganju A, Fessler RG, Smith ZA. Intraoperative neurophysiological monitoring in spine surgery: Indications, efficacy, and role of the preoperative checklist. *Neurosurgical Focus* 2012; 33(5):E10.
- Li F, Gorji R, Allott G, Modes K, Lunn R, Yang ZJ. The usefulness of intraoperative neurophysiological monitoring in cervical spine surgery. *J Neurosurg Anesthesiol* 2012; 24(3):185–90.
- Li J, Shi R. Stretch-induced nerve conduction deficits in guinea pig ex vivo nerve. *J Biomech* 2007; 40(3):569–78.
- Lykissas MG, Aichmair A, Hughes AP, Sama AA, Lebi DR, Taher F, Du JY, Cammisa FP, Girardi FP. Nerve injury after lateral lumbar interbody fusion: A review of 919 treated levels with identification of risk factors. *Spine J* 2014; 14(5):749–58.
- Lyon R, Gibson A, Burch S, Lieberman J. Increases in voltage may produce false-negatives when using transcranial motor evoked potentials to detect an isolated nerve root injury. *J Clin Monit Comput* 2010; 24(6):441–8.
- Lyon R, Burch S, Lieberman J. Mixed-muscle electrode placement (“jumping” muscles) may produce false-negative results when using transcranial motor evoked potentials to detect an isolated nerve root injury in a porcine model. *J Clin Monit Comput* 2009a; 23(6):403–8.
- Lyon R, Lieberman JA, Feiner J, Burch S. Relative efficacy of transcranial motor evoked potentials, mechanically-elicited electromyography, and evoked EMG to assess nerve root function during sustained retraction in a porcine model. *Spine (Phila Pa 1976)* 2009b; 34(16):E558–64.

- Lubińska L. Early course of Wallerian degeneration in myelinated fibres of the rat phrenic nerve. *Brain Res* 1977; 130(1):47–63.
- MacDonald DB, Skinner S, Shils J, Yingling C. Intraoperative motor evoked potential monitoring – A position statement by the American Society of Neurophysiological Monitoring. *Clin Neurophysiol* 2013; 124(12):2291–316.
- Mok JM, Lyon R, Lieberman JA, Cloyd JM, Burch S. Monitoring of nerve root injury using transcranial motor-evoked potentials in a pig model. *Spine (Phila Pa 1976)* 2008; 33(14):E465–73.
- Ochs S, Pourmand R, Si K, Friedman RN. Stretch of mammalian nerve in vitro: Effect on compound action potentials. *J. Peripher Nerv Syst* 2000; 5(4):227–35.
- Ozgur BM, Aryan HE, Pimenta L, Taylor WR. ExtremeLateral interbody fusion (XLIF): A novel surgical technique for anterior lumbar interbody fusion. *Spine J* 2006; 6(4):435–43.
- Rodgers WB, Gerber EJ, Patterson J. Intraoperative and early postoperative complications in extreme lateral interbody fusion: An analysis of 600 cases. *Spine (Phila Pa 1976)* 2011; 36(1):26–32.
- Siegel A, Sapru HN. *Essential Neuroscience: Second Edition*. Baltimore: Lippincott Williams and Wilkins; 2010.
- Silverstein J, Mermelstein L, DeWal H, Basra S. Saphenous nerve somatosensory evoked potentials: A novel technique to monitor the femoral nerve during transposas lateral lumbar interbody fusion. *Spine (Phila Pa 1976)* 2014; 39(15):1254–60.
- Sofianos DA, Briseño MR, Abrams J, Patel AA. Complications of the lateral transposas approach for lumbar interbody arthrodesis: A case series and literature review. *Clin Orthop Relat Res* 2012; 470(6):1621–32.
- Tohmeh AG, Rodgers WB, Peterson MD. Dynamically evoked, discrete-threshold electromyography in the extreme lateral interbody fusion approach. *J Neurosurg Spine* 2011;14:31–37.