SYNGAP1-RELATED INTELLECTUAL DISABILITY

TREATMENT GUIDELINES

CLINICAL CHARACTERISTICS

DEVELOPMENTAL DELAY AND INTELLECTUAL DISABILITY

The great majority of affected children present with developmental delay or intellectual disability that is typically moderate to severe but can be mild.
Early motor development is characterized by hypotonia. The average age at walking was 26 months (range: 10.5 months to 5 years). A subset of these children had an ataxic gait that remained stable or improved over time.
Language is generally impaired; a third of individuals age five years or more remain nonverbal. In those who are verbal, language development ranges from use of single words only to four-to-five-word sentences.

EPILEPSY

Approximately 84% of individuals with SYNGAP1-ID have generalized epilepsy; a subset of these were diagnosed with myoclonic astatic epilepsy (Doose syndrome) or epilepsy with myoclonic absences [Mignot et al 2016].

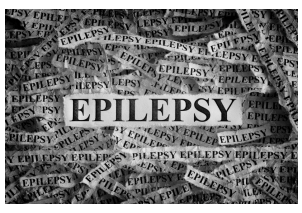

While the epilepsy responds to a single antiepileptic drug in approximately half of affected individuals, it is pharmacoresistant in the remainder. Children with refractory seizures may be diagnosed with epileptic encephalopathy (i.e., refractory seizures and cognitive slowing or regression associated with frequent ongoing epileptiform activity).

CHARACTERISTICS OF EPILEPSY

Age at onset of seizures varies between six months and seven years; mean age of seizure onset was 3.5 years in one study [Mignot et al 2016].
Seizure types include typical or atypical seizures, myoclonic jerks with or without falls, eyelid myoclonia, tonic-clonic seizures, myoclonic absences, and atonic seizures. In one study, Doose syndrome (myoclonic astatic epilepsy) was diagnosed in three of 17 individuals [Mignot et al 2016].
Electroencephalography typically shows generalized epileptic activity, frequently with a posterior predominance. Photosensitivity and fixation-off phenomenon have been observed in a number of individuals.
Brain MRI is typically normal; in rare cases, brain atrophy or delayed myelination has been reported.

AUTISM SPECTRUM DISORDER (ASD) AND OTHER BEHAVIORAL ABNORMALITIES

The occurrence of ASD could be as high as 50%. This includes stereotypic behaviors such as hand flapping, obsessions with certain objects, and poor social development. In addition, inattention, impulsivity, self-directed and other-directed aggressive behavior, elevated pain threshold, hyperacusis, and sleep disorders have been observed.

OTHER ASSOCIATED FEATURES

- **Acquired microcephaly** observed in a minority of affected individuals
- **Eye abnormalities** including strabismus
- **Musculoskeletal disorders** including hip rotation or dysplasia, kyphoscoliosis, and pes planus
- **Hypertrichosis** (predominantly on the limbs and lower spine) occasionally described
- **Gastrointestinal dysfunction** (including constipation requiring medical intervention) frequently reported; swallowing difficulties rarely reported
- **Craniofacial features**. Although some authors have suggested a subtle but consistent facial appearance (almond-shaped palpebral fissures, mildly myopathic and open-mouthed appearance) [Parker et al 2015], it is unclear if these changes are distinct enough to allow a clinician to suspect the condition in a child.

https://www.ncbi.nlm.nih.gov/pubmed/30789692

J Lloyd Holder, Jr, MD, PhD
Texas Children's Hospital
Houston, Texas
ude.mcb@redloh

Fadi F Hamdan, PhD
CHU Ste-Justine Research Center
Montreal, Quebec, Canada
ac.cq.enitsuj-ets-ehcrehcer@nadmah.idaf

Jacques L Michaud, MD
CHU Ste-Justine Research Center
Montreal, Quebec, Canada
ac.cq.enitsuj-ets-ehcrehcer@duahcim.seuqcaj