

Maxillary Hypoplasia: Differential Diagnosis of Nasal Obstruction in Infants

Amanda Lucas da Costa, MD,* Denise Manica, MD, MSc,† Michelle Manzini, MD,† Andressa Bernardi,† Juliano Adams Pérez, MD,‡ Leo Sekine, MD, MSc,‡§ Marcus Vinicius Martins Collares, MD, PhD,||¶ Gabriel Kuhl, MD,¶ and Claudia Schweiger, MD, PhD#

Abstract: Maxillary hypoplasia (MH) is a rare cause of respiratory dysfunction in infants and may occur in association with genetic abnormalities or as an isolated condition. It is included in the differential diagnosis of congenital nasal obstruction. This paper seeks to report a case series of infants with MH, discuss methods for its diagnosis, and compare computed tomography (CT) measurements of nasal cavities of infants with MH and without craniomaxillofacial abnormalities. The therapeutic approach in each patient is also described. All infants with MH admitted to a tertiary hospital between 2012 and 2015 were included. Baseline nasal endoscopy was performed at bedside. The width of the infants' nasal cavities was measured by a radiologist with experience in CT scanning of facial bones. Control patients were infants of matched sex and similar age who underwent head CT scanning for various reasons. Overall, 8 infants with MH and 8 controls were assessed. All nasal cavity dimensions of infants with MH were significantly smaller than those of control subjects. The authors conclude that the diagnosis of MH should be considered in infants with nasal obstruction and nasal cavity narrowing at nasal endoscopy.

Key Words: Choanal atresia, craniofacial abnormalities, genetic diseases, holoprosencephaly, nasal obstruction

Nasal obstruction is a major cause of respiratory dysfunction in infants, because most are obligate nasal breathers. This airway obstruction may lead to severe consequences, such as episodes of cyanosis and asphyxia, in some patients requiring endotracheal intubation. Most infants are able to breathe through the mouth only after 5 months of age.¹⁻³

Any infant presenting with symptoms such as nasal snoring and/or fatigue while suckling, pauses during breastfeeding, choking,

cyanosis, or other signs of respiratory distress relieved by crying must undergo an investigation of nasal patency.^{4,5}

The leading cause of nasal obstruction in this age group is mucosal edema secondary to idiopathic rhinitis.^{6,7} However, a diagnosis of congenital nasal anomalies should also be considered.⁸ Choanal atresia is the most common such anomaly,⁹ but the differential diagnosis also includes congenital pyriform aperture (PA) stenosis, nasolacrimal duct cyst, intranasal vascular malformations, and maxillary hypoplasia (MH).^{10,11}

Computed tomography (CT) scanning of the facial bones is the gold standard method for diagnosis of congenital nasal obstructive diseases in infants. However, there are no studies in the literature defining the normal dimensions of the nasal cavity and maxilla in this age group. An exception is the PA, which usually has a width of >8 to 11 mm.^{10,12-14}

Initially, the diagnosis of MH should be based on the signs and symptoms experienced by the patient, the presence of associated syndromes, and the exclusion of other diseases that cause nasal obstruction in infants.^{15,16} The possibility of MH should be especially considered in infants who have already been diagnosed with holoprosencephaly, Apert syndrome, solitary median maxillary central incisor syndrome, or Crouzon syndrome.^{17,18} However, patients with syndromes often have mild phenotypes and require a multidisciplinary team of pediatricians, geneticists, craniomaxillofacial surgeons, and otolaryngologists to ensure appropriate evaluation and diagnosis of all the associated malformations.⁴

The aim of this study was to report a case series of infants with MH and to discuss methods for its diagnosis, as well as to compare CT measurements of the nasal cavities of these infants with those of control subjects without craniomaxillofacial abnormalities.

MATERIALS AND METHODS

We conducted a retrospective study of all patients diagnosed with MH at our hospital between 2011 and 2015.

All infants showing signs of upper airway obstruction (stridor, snoring, nasal obstruction, cyanosis, apnea, and respiratory effort) undergo otolaryngology evaluation during hospitalization, and these data are routinely recorded in the Department of Otolaryngology for later follow-up. From this database, we selected and reviewed the records of children diagnosed with MH.

All patients underwent nasal endoscopy with a 2.4-mm diameter flexible optic, performed by the same otolaryngologist with experience in this type of procedure. If there was diagnostic suspicion of MH, the patient underwent CT scanning. The width of the nasal cavity was measured at the PA, at 2 standardized points along the lateral nasal wall corresponding to 50% and 75% of the distance between the PA and the choana (LW1 and LW2, respectively), and at the choana (Fig. 1).

Nasal cavity dimensions of case, patients were compared to those of control subjects with no craniomaxillofacial abnormalities, matched for age and sex, who had undergone CT for other reasons. All CT measurements were obtained by an experienced radiologist.

Mean and standard deviation was computed for all measurements and compared between patients with MH and controls using Student *t* test. Variables that were asymmetrically distributed were reported as the median and interquartile range, and the Mann-Whitney *U* test was performed. All statistical analyses were performed in SPSS Statistics for Windows, Version 20.0 (IBM Corp, Armonk, NY).

The study was approved by the Ethics Committee of our hospital. All procedures were in accordance with the ethical standards of the institutional and/or national research committee and with the 1964 Helsinki declaration and its later amendments or comparable ethical standards. All investigators signed a data use agreement. As this was a chart review study, informed consent requirements were waived by our institutional research ethics committee.

From the *Division of Otolaryngology, Head and Neck Surgery, Hospital de Clínicas de Porto Alegre (HCPA); †Division of Otolaryngology, HCPA; ‡Division of Radiology, HCPA; §Graduate Program in Epidemiology, Universidade Federal do Rio Grande do Sul (UFRGS); ||Department of Surgery, UFRGS; ¶Division of Craniomaxillofacial Surgery, HCPA; and #Department of Otolaryngology and Ophthalmology, UFRGS, Porto Alegre, Brazil.

Received March 1, 2017.

Accepted for publication March 29, 2017.

Address correspondence and reprint requests to Amanda Lucas da Costa, MD, Av. Coronel João Batista S. da Silveira e Souza, 180/603, 94920-100 Cachoeirinha, RS, Brazil;

E-mail: amandale_otorrino@hotmail.com

The authors report no conflicts of interest.
Copyright © 2017 by Mutaz B. Habal, MD
ISSN: 1049-2275

DOI: 10.1097/SCS.0000000000003868

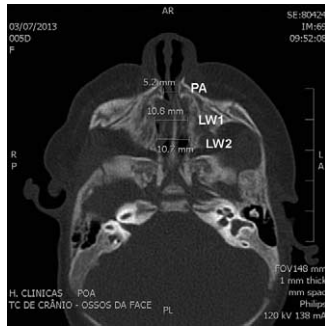


FIGURE 1. Measurement sites shown on a computed tomography scan. LW1, width of the nasal cavity at 50% of the distance between the choana and the PA; LW2, width of the nasal cavity at 75% of the distance between the choana and the PA; PA, width of the nasal cavity at the pyriform aperture.

RESULTS

During the study, we found data from 316 patients with upper airway obstruction. Of those, 9 patients were diagnosed with MH. Figure 2 shows a flowchart of the diagnostic workup of nasal obstruction in infants, while Table 1 describes the patients in detail.

The first signs that indicated MH were respiratory effort and difficulty passing a suction probe through the nostrils. In all patients, the pediatrician’s first diagnostic hypothesis was choanal atresia. A baseline nasal endoscopy was performed in all patients, but advancing a flexible optic through the PA was always difficult, raising the suspicion of either PA stenosis or MH.

Computed tomography scan of the facial bones showed different degrees of nasal cavity narrowing. The CT scans were also important for assessment of other genetic abnormalities associated with MH, such as holoprosencephaly and solitary median maxillary central incisor syndrome.

All nasal cavity dimensions of patients were significantly narrower than those of controls ($P < 0.05$; Table 2), from the PA to the choana. This confirmed the diagnosis of MH in all patients.

DISCUSSION

Maxillary hypoplasia can be diagnosed by a CT scan of the facial bones showing a shift in the position of the medial processes of the maxilla, resulting in narrowing of both anterior and posterior parts

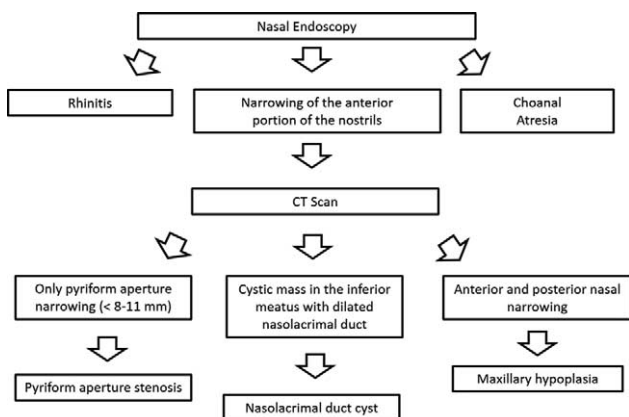


FIGURE 2. Diagnostic flowchart for nasal obstruction in infants.

of the nasal cavity.^{8,19} However, the range of normal dimensions of these structures in healthy subjects is not available in the literature. Therefore, an overall assessment of the patient’s facial and nasal anatomy should be performed, as well as of associated signs and symptoms and of occasional phenotypic characteristics that may be related to syndromes known to cause hypoplasia of the middle third of the face.^{20,21}

A recent study showed that most patients diagnosed with congenital PA stenosis in fact have MH, that is, narrowing of more than two-thirds of the anterior nasal cavity, although the authors did not distinguish between these 2 diseases in their paper.^{12,20}

Diagnostic evaluation of nasal obstruction should include a nasal endoscopy, which is usually the first procedure to be performed, since it can be done at bedside without sedation. In addition, it enables immediate diagnosis of some nasal diseases in infants. However, in patients with anterior nasal cavity narrowing, nasal endoscopy raises 2 diagnostic hypotheses, MH and congenital PA stenosis,^{6,8,12,16,19,20} and is unable to differentiate one from the other. Thus, it should be followed by a CT scan of the facial bones, which shows the dimension of the nasal cavity in its full extension. The combination of these 2 procedures seems to be the best option for diagnostic investigation of nasal obstruction in infants.^{21,22}

The normal nasal cavity dimensions of infants have not been defined in the literature. At the time of this writing, the diagnosis of MH in the infant with nasal obstruction is based on the subjective impression of nasal cavity narrowing at nasal endoscopy and on the observation of significant maxillary narrowing on CT scan.⁴ The present study reported a case series of patients that showed significantly narrower nasal cavities at CT scan compared with controls, and, along with clinical symptoms and nasal endoscopy data, had a confirmed diagnosis of MH. With such a small number of patients, defining a reference range for nasal cavity dimensions is not possible yet. However, the values found for 2 measurement sites (LW1 and LW2) can be considered good analysis parameters. In a near future, larger studies will be able to establish a reference range for LW1 and LW2, making the diagnosis of MH more accurate.

Distinguishing between MH and congenital PA stenosis is the greatest challenge in such patients. This distinction is extremely important, as surgical treatment differs between the 2 conditions. In patients with congenital PA stenosis, simple anterior drilling of the nasal process of the maxilla is sufficient to improve nasal patency.³ Maxillary hypoplasia, however, usually requires expansion of the nasal cavity in its entire anteroposterior extent with the placement of maxillary distractors. Selection of the inappropriate surgical technique due to misdiagnosis will lead to treatment failure, which can be disastrous for infants who have multiple associated malformations.^{8,16,23}

Diagnostic suspicion is facilitated if the infant has already been diagnosed with a syndrome known to be associated with one of the conditions. In some patients, however, nasal obstruction is the presenting symptom. In such patients, the otolaryngologist should make an initial assessment and diagnosis, prompting investigation of associated malformations in other organs. In other cases, such as patients number 2 and 8, hypoplasia was an isolated finding not associated with known syndromes, making diagnostic confirmation more challenging.

Diagnosis should be followed by determination of the therapeutic approach for each patient. The first step is to evaluate how urgent a procedure for airway protection should be to prevent sequelae.^{5,8} Infants with symptoms of severe nasal obstruction, including respiratory effort and cyanosis, must be intubated immediately. In some patients, if definitive treatment would take longer than a few weeks or if the infant has poor prognosis, tracheostomy is required.^{7,9} The best timing for definitive surgical intervention should be discussed among medical teams and

TABLE 1. Patients With Maxillary Hypoplasia From 2011 to 2015

Patients	Signs and Symptoms	Syndrome	TCT	Therapeutic Approach and Follow-Up
1. Female, 1-d-old brother died at 5 d of life due to holoprosencephaly—severe phenotype	Episodes of cyanosis, bradycardia, and ventilatory effort	Holoprosencephaly type 5—mild phenotype	No	Maxillary distraction with symptomatic improvement
2. Male, 10 d old	Severe upper airway obstruction with intense ventilatory effort requiring endotracheal intubation at first day of life	None diagnosed	Yes	Maxillary distraction—ongoing
3. Male, 30 d old	Respiratory distress and fatigue while suckling	Solitary median maxillary central incisor syndrome	No	Maxillary distraction. 6-mo follow-up after distractor removal: partial improvement in breathing; persistent snoring and difficulty advancing optical fiber
4. Male, 3 d old, syndactyly under investigation	Tachypnea and subcostal retractions—oxygen administered by hood	Apert syndrome	No	Patient tolerated no administration of oxygen polysomnography showed snoring, but no apnea. Patient was able to breathe through mouth and subsequently underwent surgery
5. Male, 1 d old	Mild ventilatory effort	Holoprosencephaly	No	Patient was able to breathe through mouth. Combined neurosurgery and craniomaxillofacial surgery in the coming months
6. Female, 10 mo old	Severe respiratory dysfunction at birth requiring endotracheal intubation and subsequent TCT at another hospital	Holoprosencephaly	Yes	TCT was maintained due to severity of associated neurologic malformations
7. Male, 2 mo old	Severe respiratory dysfunction at birth requiring endotracheal intubation	None diagnosed	No	Patient was able to breathe through mouth and subsequently underwent surgery
8. Male, age	Respiratory failure at birth with improvement after intubation	None diagnosed	Yes	Maxillary distraction

TCT, tracheostomy.

should take into account symptom severity and patient prognosis.¹⁰ Outcome depends on other associated malformations and symptom severity in each patient.^{17,24}

Maxillary hypoplasia is a rare condition that should be considered in the differential diagnosis of infants with nasal obstruction, particularly those with other associated malformations. Diagnostic evaluation should include nasal endoscopy and CT scan of facial bones. The latter is essential to distinguish MH from congenital PA stenosis. However, the reference range for nasal

cavity dimensions of infants must still be defined to establish the correct differential diagnosis in this age group.

REFERENCES

- Endo LH, Montenegro MCS. Obstrução nasal no recém nascido e na criança. *Tratado de otorrinolaringologia*. São Paulo, Brazil: Rocca; 2003
- Manica D, Smith MM, Schweiger C, et al. Nasal obstruction of the newborn: a differential diagnosis. *Arq Int Otorrinolaringol* 2009;13:340–345
- Serrano TL, Pfeilsticker L, Silva V, et al. Newborn nasal obstruction due to congenital nasal pyriform aperture stenosis. *Allergy Rhinol (Providence)* 2016;7:37–41
- Sohal M, Schoem SR. Disorders of the neonatal nasal cavity: fundamentals for practice. *Semin Fetal Neonatal Med* 2016;21:263–269
- Goldstein NA, Gitman L. Nasal obstruction in newborns. *Pediatr Clin North Am* 2015;16:e36–e46
- Brachlow A, Schwartz RH, Bahadori RS. Intranasal mucocele of the nasolacrimal duct: an important cause of neonatal nasal obstruction. *Clin Pediatr (Phila)* 2004;43:479–481
- Chirico G, Quartarone G, Malfet P. Nasal congestion in infants and children: a literature review on efficacy and safety of non-pharmacological treatments. *Minerva Pediatr* 2014;66:549–557
- Likus W, Bajor G, Gruszczynska K, et al. Nasal region dimensions in children: a CT study and clinical implications. *Biomed Res Int* 2014;2014:125810
- Eladl HM, Khafagy YW. Endoscopic bilateral congenital choanal atresia repair of 112 cases, evolving concept and technical experience. *Int J Pediatr Otorhinolaryngol* 2016;85:40–45

TABLE 2. Comparison Between Means of Computed Tomographic Measurements in Patient and Control Subjects (n = 8 per Group)

Measurement	Controls*	Maxillary Hypoplasia*	P
PA	13.6 mm (1.2)	6.1 mm (1.3)	<0.001 [†]
LW1	15.5 mm (1.6)	8.5 mm (3.1)	<0.001 [‡]
LW2	14.9 mm (1.3)	11.0 mm (0.8)	<0.001 [‡]
Choana	14.4 mm (2.2)	11.7 mm (2.0)	0.019 [‡]

LW1, width of the nasal cavity at 50% of the distance between the choana and the PA; LW2, width of the nasal cavity at 75% of the distance between the choana and the PA; PA, pyriform aperture.

*Mean (standard deviation).

[†]Mann–Whitney U test.

[‡]Student t test.

10. Moreddu E, Le Treut-Gay C, Triglia JM, et al. Congenital nasal pyriform aperture stenosis: elaboration of a management algorithm from 25 years of experience. *Int J Pediatr Otorhinolaryngol* 2016; 83:7–11
11. Rao A, Godehal SM, Patil AR, et al. Congenital nasal pyriform aperture stenosis: a rare cause of neonatal nasal airway obstruction. *BJR Case Rep* 2015;2015:00006
12. Reeves TD, Discolo CM, White DR. Nasal cavity dimensions in congenital pyriform aperture stenosis. *Int J Pediatr Otorhinolaryngol* 2013;77:1830–1832
13. Yang S, Orta P II, Renk EM, et al. Congenital nasal pyriform aperture stenosis in association with solitary median maxillary central incisor: unique radiologic features. *Radiol Case Rep* 2016;11:178–181
14. Gonik NJ, Cheng J, Lesser M, et al. Patient selection in congenital pyriform aperture stenosis repair—14 year experience and systematic review of literature. *Int J Pediatr Otorhinolaryngol* 2015;79:235–239
15. Gnagi SH, Schraff SA. Nasal obstruction in newborns. *Pediatr Clin North Am* 2013;60:903–922
16. Teo DT, Mitchell RB. Pediatric obstructive sleep apnea: diagnosis and management. In: Pang KP, Rotenberb BW, Woodson BT, eds. *Advanced surgical techniques in snoring and obstructive sleep apnea*. San Diego, CA: Plural Publishing; 2013
17. Vijayasekaran S, Lioy J, Maschhoff K. Airway disorders of the fetus and neonate: an overview. *Semin Fetal Neonatal Med* 2016;21: 220–229
18. Tan HL, Kheirandish-Gozal L, Abel F, et al. Craniofacial syndromes and sleep-related breathing disorders. *Sleep Med Rev* 2016;27:74–88
19. Lee KS, Yang CC, Huang JK, et al. Congenital pyriform aperture stenosis: surgery and evaluation with three-dimensional computed tomography. *Laryngoscope* 2002;112:918–921
20. Lin KL, Lee KS, Yang CC, et al. The natural course of congenital nasal pyriform aperture stenosis. *Laryngoscope* 2016;126:2399–2402
21. Broome M, Vial Y, Jacquemont S, et al. Complete maxillo-mandibular syngnathia in a newborn with multiple congenital malformations. *Pediatr Neonatol* 2016;57:65–68
22. Hengerer AS, Brickman TM, Jeyakumar A. Choanal atresia: embryologic analysis and evolution of treatment, a 30-year experience. *Laryngoscope* 2008;118:862–866
23. Wine TM, Dedhia K, Chi DH. Congenital nasal pyriform aperture stenosis: is there a role for nasal dilation? *JAMA Otolaryngol Head Neck Surg* 2014;140:352–356
24. Van Den Abbeele T, Triglia JM, Francois M, et al. Congenital nasal pyriform aperture stenosis: diagnosis and management of 20 cases. *Ann Otol Rhinol Laryngol* 2001;110:70–75