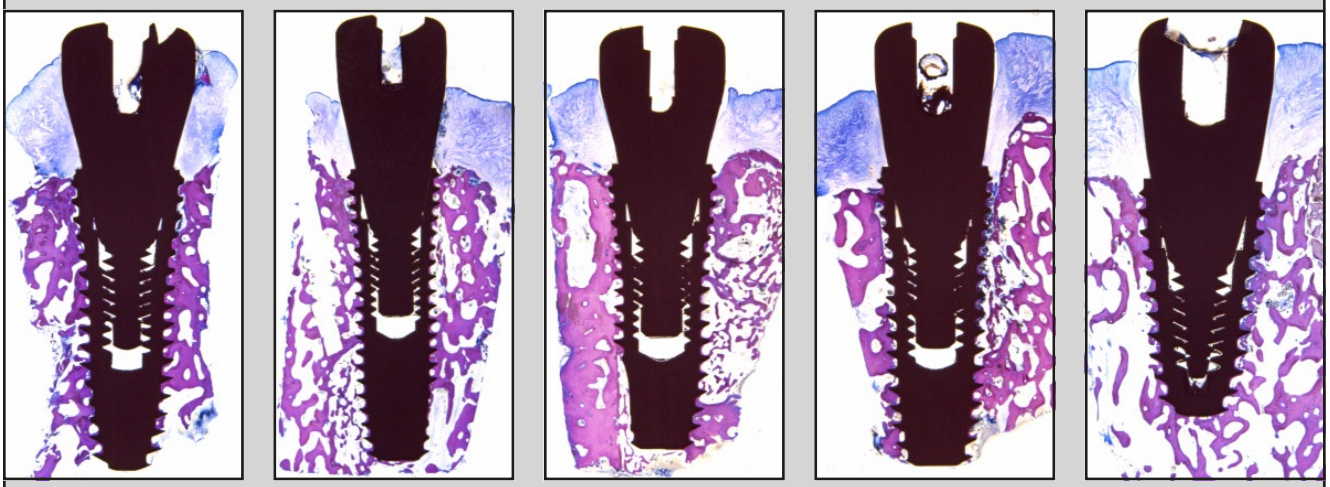

Clinical and Histologic Evaluations of Immediately Placed SLA Dental Implants

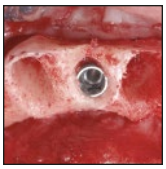

Myron Nevins, DDS[1]/Stefano Parma-Benfenati, DDS[2]
Cosmin Sava, DDS[3]/Catalin Sava, DDS[3]
Franco Quinti, MD, DDS[4]/Primo Galletti, MD, DDS[5]
Gerardo Mendoza-Azpur, DDS, MSc[6]/Erik Valdivia, DDS, MSc[7]
Yong-Han Koo, DDS[8]/David M. Kim, DDS, DMSc[9]

The goal of this investigation was to evaluate the bone-to-implant contact (BIC) of dental implants placed into fresh extraction sockets without pre-existing periapical pathology. When the extraction sites exhibited a gap distance of > 2 mm, autogenous bone harvested from surrounding surgical sites was grafted to fill that gap with no barrier membranes. All implants were clinically stable and successful at 6 months postoperative. The histologic examination demonstrated an average of 66.2% BIC for all five immediately placed dental implants. The results of this study provided sufficient histologic and histomorphometric knowledge to support immediate dental implant placement in carefully selected clinical scenarios.
Int J Periodontics Restorative Dent 2018;38:165–170. doi: 10.11607/prd.3558

[1]Associate Professor, Part-Time, Division of Periodontology, Department of Oral Medicine, Infection and Immunity, Harvard School of Dental Medicine, Boston, Massachusetts, USA.
[2]Teaching Professor at Master's Program in Periodontology, Dental School, University of Turin, Italy; Teaching Professor at Master Degree in Surgery and Oral Pathology, University of Parma, Italy.
[3]Private Practice, Bistrita, Romania.
[4]Private Practice Limited to Periodontology and Implantology, Arezzo, Italy.
[5]Private Practice Limited to Prosthodontics, Ferrara, Italy.
[6]Chairman, Department of Periodontology, School of Dentistry, Universidad Cientifica del Sur, Lima, Peru.
[7]Assistant Professor, Department of Periodontology, School of Dentistry, Universidad Cientifica del Sur, Lima, Peru.
[8]Lecturer, Part-Time, Division of Periodontology, Department of Oral Medicine, Infection and Immunity, Harvard School of Dental Medicine, Boston, Massachusetts, USA.
[9]Associate Professor, Division of Periodontology, Department of Oral Medicine, Infection and Immunity, Harvard School of Dental Medicine, Boston, Massachusetts, USA.

Correspondence to: Dr David M. Kim, Harvard School of Dental Medicine, Department of Oral Medicine, Infection and Immunity, 188 Longwood Avenue, Boston, MA 02115, USA. Fax: 617-432-1897. Email: dkim@hsdm.harvard.edu

Dental implants are routinely placed into extraction sites with little clinical evidence to ensure bone-to-implant contact (BIC) in human dentitions. This investigation was initiated to assess BIC in immediately placed implants. Human histologic evidence of successfully osseointegrated implants is extremely rare in the literature due to lack of opportunities to retrieve implants in humans.[1–5] A recent clinical study retrieved eight sandblasted with large grit and acid-etched (SLA)-surface dental implants placed into healed ridges from patients requiring full-mouth rehabilitation.[6]

As many clinicians and patients seek immediate implant placement for reasons including shorter surgical time, lower cost, and fewer office visits, a clinical study was conducted to provide a short-term observation of immediately placed implants in fresh extraction sockets without pre-existing apical pathology. This study examined the BIC of implants with a double-threaded tapered body design, internal conical connection, platform switching, and a cutting flat end.

Materials and Methods

Implant Surgery

Five individuals requiring dental implant rehabilitation agreed to sign

Fig 1 (a) *A 68-year-old woman presented with failing maxillary dentition and agreed to receive dental implant restoration.* (b) *Periapical radiographs revealed few remaining teeth with moderate to severe bone loss associated with short roots.*

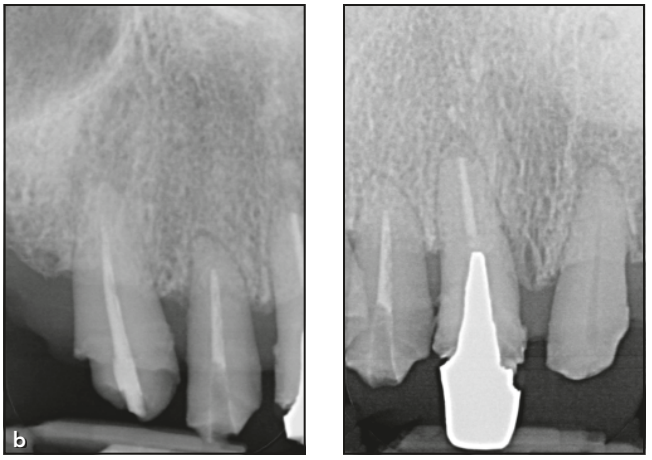

an informed consent form based on the Helsinki Declaration of 1975, as revised in 2000. The study was approved by the institutional review board of Regina Maria Hospital in Bucharest, Romania. Pre- and postsurgical clinical examinations were performed and thorough oral hygiene instruction given during each patient visit. The screening process involved clinical and radiographic examinations to determine patient eligibility. All patients presented with periodontally compromised dentitions requiring multiple extractions (Fig 1). On the day of the surgery, all procedures performed were routine with the exception of a selection of the planned biopsy (study) dental implants. Atraumatic extractions were performed to preserve the remaining walls of bone, and dental implant (SuperLine, Dentium) surgeries were conducted as suggested by the manufacturer under local anesthesia and sterile conditions (Figs 2a and 2b). Study implant sites had to present with intact remaining bone walls without pre-existing periapical pathology (Fig 2b). When the extraction sites exhibited a gap distance of > 2 mm, autogenous bone harvested from surrounding surgical sites was grafted to fill that gap with no barrier membranes. Additional nonstudy implants were placed to support final restoration. All implants received healing abutments in a nonsubmerged position, and nonresorbable sutures were placed to position the flaps (Figs 2c and 2d).

There were no adverse events, and the patients kept the planned appointments for observation. Periapical radiographs were made at the 6-month surgical visit (Fig 3).

Dental Implant Biopsy

All surgical sites were allowed to heal for 6 months before en bloc removal of five preselected implants. A piezosurgical instrument (Mectrony) was used to biopsy implants that were 3.6 mm in width and 7 to 12 mm in length. These were immediately immersed in a fixative solution for histologic preparation.

Histologic and Histomorphometric Analyses

Fixed samples were dehydrated in a graded series of ethanol (60%, 80%, 96%, and absolute ethanol) using a dehydration system with agitation and vacuum. The blocks were infiltrated with Kulzer Technovit 7200 VLC-resin. Infiltrated specimens were placed into embedding molds, and polymerization was performed under blue and white light. Polymerized blocks were sectioned in a mesiodistal direction and parallel to the long axis of each implant. The slices were reduced by microgrinding and polishing using an Exakt grinding unit to an even thickness of 30 to 40 μm. Sections were stained with RBS, counterstained with acid fuchsin, and examined using a Leica MZ16 stereomicroscope and a Leica 6000DRB light microscope. Histomorphometric measurements were performed using software (ImageAcess, Imagic) to calculate the percentage of mineralized bone, soft tissue components (connective tissue and/or

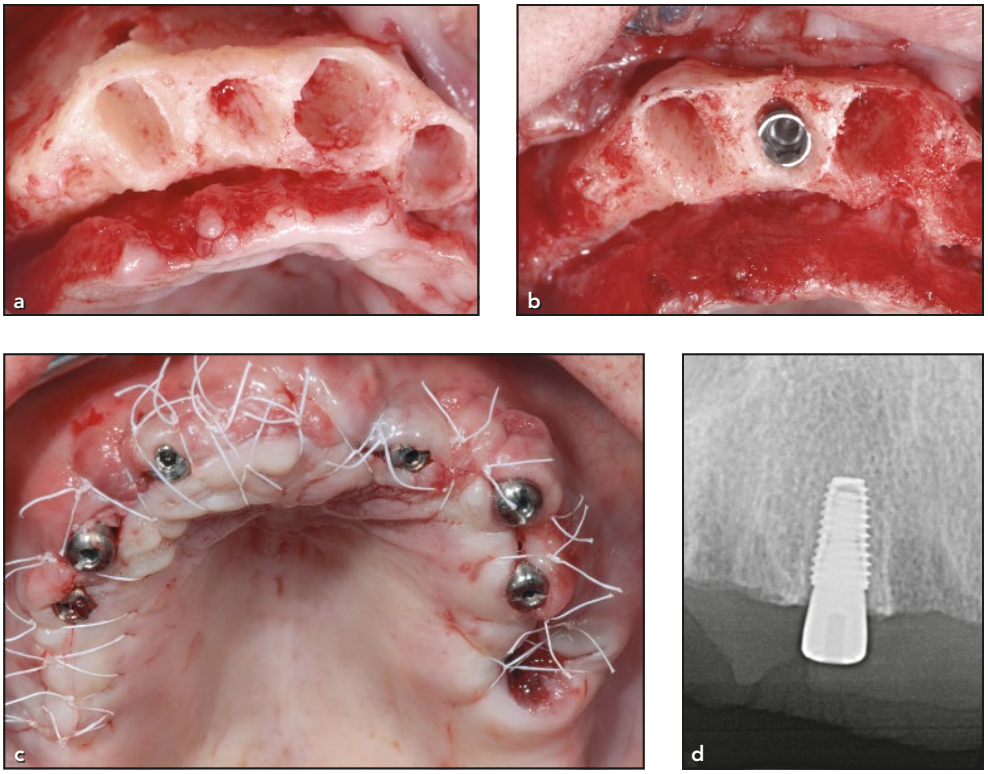

Fig 2 (a) *Maxillary teeth were extracted and thorough socket degranulation was performed.* (b) *SLA surface dental implant has been immediately placed into the extraction socket and this implant was chosen for biopsy 6 months later.* (c) *The patient received six additional dental implants, along with healing abutments.* (d) *A periapical radiograph of the planned biopsy dental implant.*

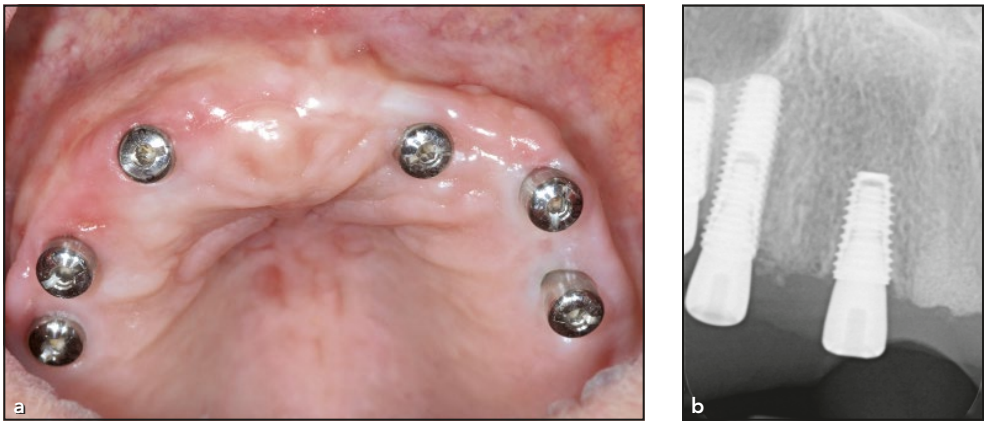

Fig 3 (a) *At the follow-up visit 6 months after implant surgery, the patient presented with very good oral hygiene and healthy periodontium surrounding the healing abutments.* (b) *A new periapical radiograph was taken for the planned implant biopsy.*

bone marrow) and residual graft particles along the BIC surface.

Results

Clinical and Radiographic Observations

All dental implants were successfully placed and achieved clinical osseointegration with no signs of adverse events (Fig 3). Necessary dental implants were placed for five patients, and biopsies were performed on five implants for evaluation. All biopsy reconstructive areas healed uneventfully. Radiographic evaluation demonstrated excellent maintenance of crestal bone level around dental implants. Each patient was prosthetically reconstructed.

Histologic Observations

All histologic specimens demonstrated adequate BIC (Fig 4). Newly formed dense bone was found in contact with the implant surfaces along with normal bone marrow spaces and vasculature. The crestal bone was occlusal to the threads in most specimens.

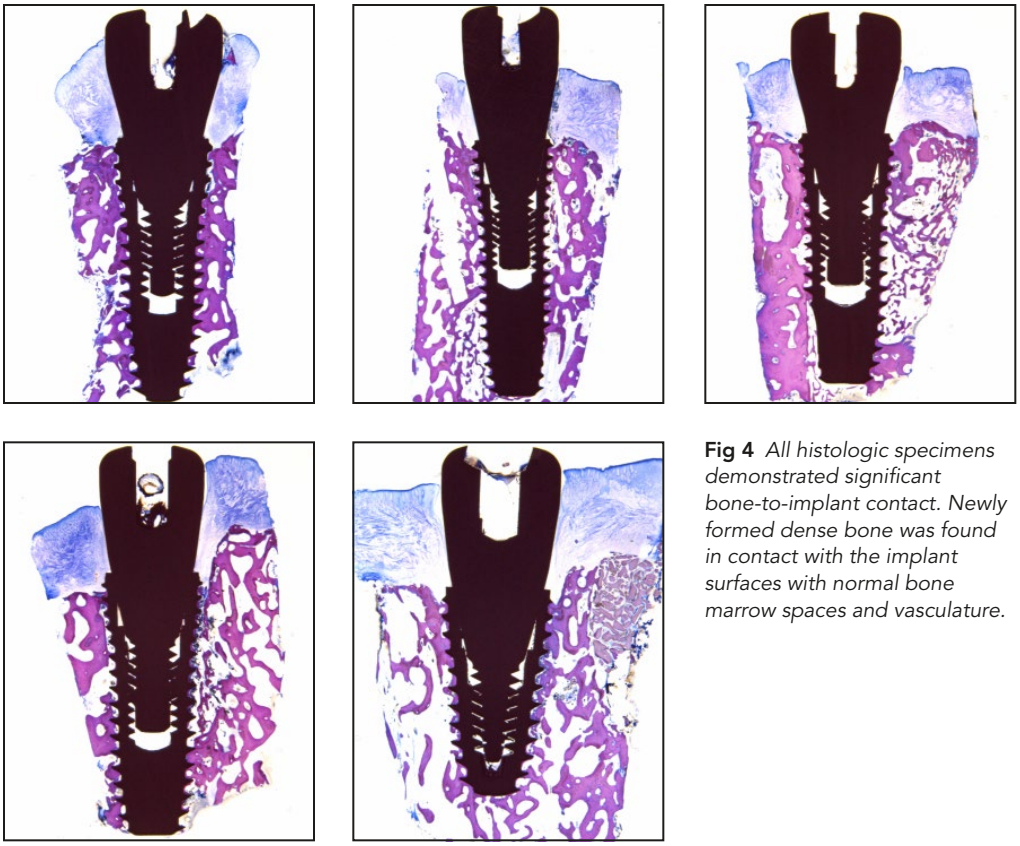

Fig 4 *All histologic specimens demonstrated significant bone-to-implant contact. Newly formed dense bone was found in contact with the implant surfaces with normal bone marrow spaces and vasculature.*

Histomorphometric Analysis

Light microscopy revealed excellent BIC in all groups. The mean BIC was 66.2% for all five implants, ranging from 57.9% to 70.5%.

Discussion

Osseointegration of titanium dental implants has been long demonstrated to be safe and efficacious. The initial publication of dental implant placement into an extraction socket was in 1989.[7] The advantages included fewer surgical procedures, reduced cost, and fewer patient visits.[8,9] Case reports have documented excellent healing and shorter treatment time together with the perception of preservation of alveolar bone.[8,9] Dental implants placed in infected sites with periapical lesions have been shown to be successful but were excluded in this study.[10–12]

Case selection and the surgeon's clinical experience in implant dentistry is of utmost importance in immediate dental implant therapy. A 3-year retrospective chart review of immediate dental implants placed by either experienced senior surgeons (expert group) or residents (nonexpert group) noted a significantly higher (P = .0044) bone loss in the nonexpert group than in the expert group.[13] In addition, more gingival recession and less satisfaction were reported for patients treated by nonexperts.

A review of the literature confirmed that immediate dental implants placed in an esthetic zone often resulted in midfacial tissue recession, possibly due to thin tissue biotype, malpositioned implants, and thin or damaged buccal bone after extraction.[9,14,15] Thus, strict clinical and radiographic criteria, such as intact buccal bone, thick tissue biotype, absence of acute infection, and sufficient bone volume in both horizontal and vertical dimensions, should be fulfilled before considering this treatment modality.[9] In addition, modifications in implant design and

surgical techniques resulting in use of platform-switched dental implants, flapless surgical technique, insertion of grafting material between the implant and the socket wall, immediate provisionalization, and addition of a connective tissue graft should be considered to preserve soft and hard tissue formation around immediately placed implants.[16–20]

Implants with a moderately rough surface allows for macrorough surface topography from sandblasting and microrough surface topography from acid-etching have been proven to be successful.[21–25] A number of university and hospital-based treatment centers have demonstrated successful results with SLA surface implants.[26–33] In a 10-year retrospective radiographic study of 242 SLA surface dental implants, Park et al[33] reported a 97.9% implant survival rate and an overall mean bone loss of −0.28 ± 0.05 mm.[33] Several preclinical and clinical studies demonstrate its safety and effectiveness in native and regenerated bone.[6,34,35]

The BIC observed histologically in this investigation was comparable to that seen in a clinical study on implants placed into healed ridges.[6]

A limitation of this study is that the biopsy specimens were not prosthetically loaded. Nonetheless, adjacent loaded implants did not experience significant crestal bone remodeling but demonstrated an ability to support prostheses (Fig 5).

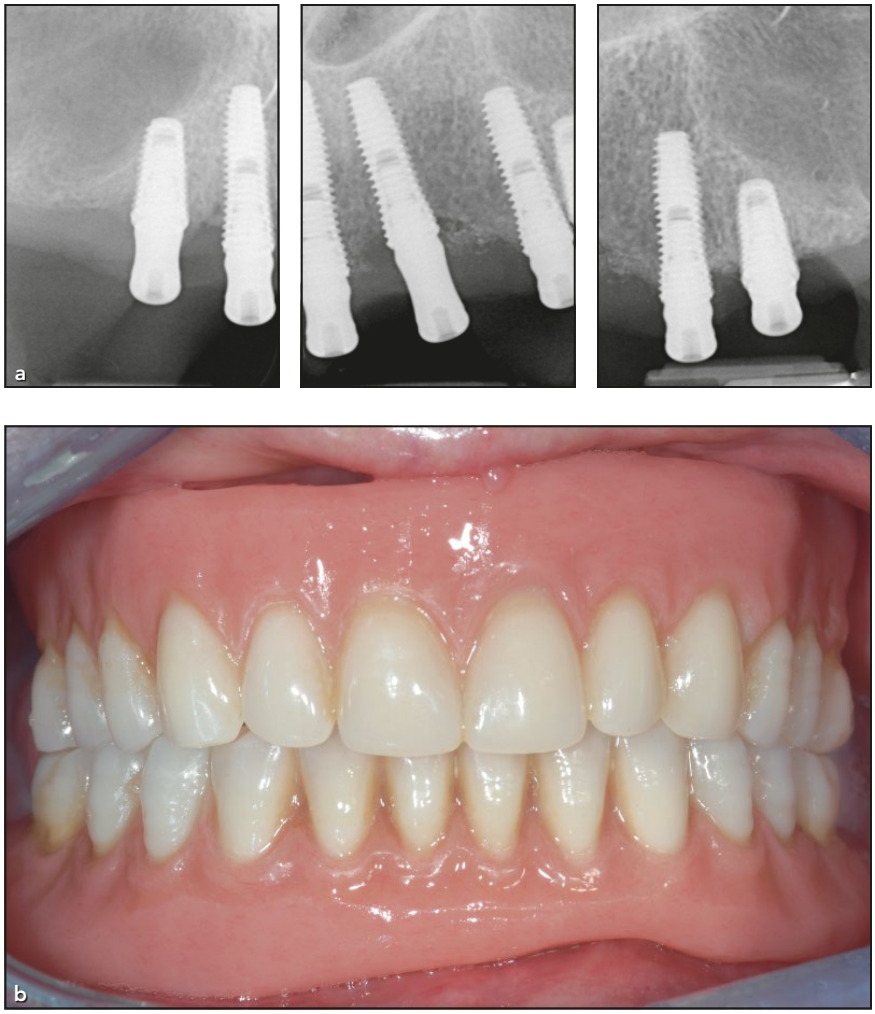

Fig 5 (a) *At 1 year postrestoration, radiographs demonstrated good bone level on nonstudy implants.* (b) *The patient received new maxillary and mandibular restorations that improved her oral function.*

Conclusions

The results of this human histologic investigation confirm the osseointegration of immediately placed SLA surface dental implants. All specimens demonstrated sufficient BIC to support forthcoming prostheses.

Acknowledgments

This study was supported by a grant from Dentium Co, Ltd. The authors reported no conflicts of interest related to this study.

References

1. Uehara T, Takaoka K, Ito K. Histological evidence of osseointegration in human retrieved fractured hydroxyapatite-coated screw-type implants: A case report. Clin Oral Implants Res 2004;15:540–545.
2. Albrektsson T, Eriksson AR, Friberg B, et al. Histologic investigations on 33 retrieved Nobelpharma implants. Clin Mater 1993;12:1–9.

3. Iamoni F, Rasperini G, Trisi P, Simon M. Histomorphometric analysis of a half hydroxyapatite-coated implant in humans: A pilot study. Int J Oral Maxillofac Implants 1999;14:729–735.
4. Scarano A, Degidi M, Iezzi G, Petrone G, Piattelli A. Correlation between implant stability quotient and bone-implant contact: A retrospective histological and histomorphometrical study of seven titanium implants retrieved from humans. Clin Implant Dent Relat Res 2006;8:218–222.
5. Nevins M, Nevins ML, Camelo M, Boyesen JL, Kim DM. Human histologic evidence of a connective tissue attachment to a dental implant. Int J Periodontics Restorative Dent 2008;28:111–121.
6. Nevins M, Parma-Benfenati S, Quinti F, et al. Clinical and histologic evaluations of SLA dental implants. Int J Periodontics Restorative Dent 2017;37:175–181.
7. Lazzara RJ. Immediate implant placement into extraction sites: Surgical and restorative advantages. Int J Periodontics Restorative Dent 1989;9:332–343.
8. Werbitt MJ, Goldberg PV. The immediate implant: Bone preservation and bone regeneration. Int J Periodontics Restorative Dent 1992;12:206–217.
9. Buser D, Chappuis V, Belser UC, Chen S. Implant placement post extraction in esthetic single tooth sites: When immediate, when early, when late? Periodontol 2000 2017;73:84–102.
10. Bell CL, Diehl D, Bell BM, Bell RE. The immediate placement of dental implants into extraction sites with periapical lesions: A retrospective chart review. J Oral Maxillofac Surg 2011;69:1623–1627.
11. Marconcini S, Barone A, Gelpi F, Briguglio F, Covani U. Immediate implant placement in infected sites: A case series. J Periodontol 2013;84:196–202.
12. Jung RE, Zaugg B, Philipp AO, Truninger TC, Siegenthaler DW, Hämmerle CH. A prospective, controlled clinical trial evaluating the clinical radiological and aesthetic outcome after 5 years of immediately placed implants in sockets exhibiting periapical pathology. Clin Oral Implants Res 2013;24:839–846.
13. Barone A, Toti P, Marconcini S, Derchi G, Saverio M, Covani U. Esthetic outcome of implants placed in fresh extraction sockets by clinicians with or without experience: A medium-term retrospective evaluation. Int J Oral Maxillofac Implants 2016;31: 1397–1406.
14. Kan JY, Rungcharassaeng K, Sclar A, Lozada JL. Effects of the facial osseous defect morphology on gingival dynamics after immediate tooth replacement and guided bone regeneration: 1-year results. J Oral Maxillofac Surg 2007;65(Suppl 1):13–19.
15. Chen ST, Buser D. Esthetic outcomes following immediate and early implant placement in the anterior maxilla—A systematic review. Int J Oral Maxillofac Implants. 2014;29(suppl):s186–s215.
16. Kinaia BM, Shah M, Neely AL, Goodis HE. Crestal bone level changes around immediately placed implants: A systematic review and meta-analyses with at least 12 months' follow-up after functional loading. J Periodontol 2014;85:1537–1548.
17. de Carvalho BC, de Carvalho EM, Consani RL. Flapless single-tooth immediate implant placement. Int J Oral Maxillofac Implants 2013;28:783–789.
18. Cosyn J, Eghbali A, De Bryun H, Collys K, Cleymaet R, De Rouck T. Immediate single-tooth implants in the anterior maxilla: 3-year results of a case series on hard and soft tissue response and aesthetics. J Clin Periodontol 2011;38:746–753.
19. Cardaropoli D, Gaveglio L, Gherlone E, Cardaropoli G. Soft tissue contour changes at immediate implants: A randomized controlled clinical study. Int J Periodontics Restorative Dent 2014;34: 631–637.
20. Rungcharassaeng K, Kan JY, Yoshino S, Morimoto T, Zimmerman G. Immediate implant placement and provisionalization with and without a connective tissue graft: An analysis of facial gingival tissue thickness. Int J Periodontics Restorative Dent 2012;32:657–663.
21. Buser D, Schenk RK, Steinemann S, Fiorellini JP, Fox CH, Stich H. Influence of surface characteristics on bone integration of titanium implants. A histomorphometric study in miniature pigs. J Biomed Mater Res 1991;25:889–902.
22. Cochran DL, Nummikoski PV, Higginbottom FL, Hermann JS, Makins SR, Buser D. Evaluation of an endosseous titanium implant with a sandblasted and acid-etched surface in the canine mandible: Radiographic results. Clin Oral Implants Res 1996;7:240–252.
23. Bornstein MM, Schmid B, Belser UC, Lussi A, Buser D. Early loading of nonsubmerged titanium implants with a sandblasted and acid-etched surface. 5-year results of a prospective study in partially edentulous patients. Clin Oral Implants Res 2005;16:631–638.
24. Roccuzzo M, Aglietta M, Bunino M, Bonino L. Early loading of sandblasted and acid-etched implants: A randomized-controlled double-blind split-mouth study. Five-year results. Clin Oral Implants Res 2008;19:148–152.
25. Cochran DL, Jackson JM, Bernard JP, et al. A 5-year prospective multicenter study of early loaded titanium implants with a sandblasted and acid-etched surface. Int J Oral Maxillofac Implants 2011;26: 1324–1332.
26. Kim SJ, Kim MR, Rim JS, Chung SM, Shin SW. Comparison of implant stability after different implant surface treatments in dog bone. J Appl Oral Sci 2010;18: 415–420.
27. Jung UW, Kim S, Kim YH, Cha JK, Lee IS, Choi SH. Osseointegration of dental implants installed without mechanical engagement: A histometric analysis in dogs. Clin Oral Implants Res 2012;23:1297–1301.
28. Kim H, Choi SH, Ryu JJ, Koh SY, Park JH, Lee IS. The biocompatibility of SLA-treated titanium implants. Biomed Mater 2008;3:025011.
29. Lee JY, Park HJ, Kim JE, et al. A 5-year retrospective clinical study of the Dentium implants. J Adv Prosthodont 2011;3: 229–235.
30. Cha JK, Park JC, Jung UW, Kim CS, Cho KS, Choi SH. Case series of maxillary sinus augmentation with biphasic calcium phosphate: A clinical and radiographic study. J Periodontal Implant Sci 2011;41:98–104.
31. Cha HS, Kim A, Nowzari H, Chang HS, Ahn KM. Simultaneous sinus lift and implant installation: Prospective study of consecutive two hundred seventeen sinus lift and four hundred sixty-two implants. Clin Implant Dent Relat Res 2014;16:337–347.
32. Lee JS, Kim HM, Kim CS, Choi SH, Chai JK, Jung UW. Long-term retrospective study of narrow implants for fixed dental prostheses. Clin Oral Implants Res 2013; 24:847–852.
33. Park W, Park Y, Park H, et al. A 10-year retrospective radiographic study of implantium dental implants. Int J Periodontics Restorative Dent 2015;35:49–54.
34. Kim DM, Nevins ML, Lin Z, et al. The clinical and histologic outcome of dental implant in large ridge defect regenerated with alloplast: A randomized controlled preclinical trial. J Oral Implantol 2013;39:148–153.
35. Yi HY, Park YS, Pippenger BE, Lee B, Miron RJ, Dard M. Dimensional changes following immediate and delayed implant placement: A histomorphometric study in the canine. Int J Oral Maxillofac Implants 2017;32:541–546.