


IVC FILTER OCCLUSION



Physician

Basel Refai, MD, RVT, RPVI, FSVM

Facility

Lake Martin Vein & Laser Center

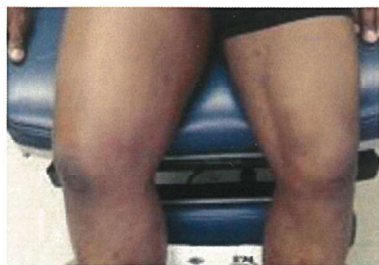Alexander City, AL 35010

256-212-9300

www.lakemartinvein.com

Clinical History

- 72 year old with history of DVT (deep vein thrombosis) and PTE (pulmonary thromboembolism).
- Underwent filter placement at the time, continued on anticoagulation therapy.
- Was re-admitted a year after with pneumonia and was switched from Coumadin to factor Xa inhibitor.
- Six months on factor Xa inhibitor therapy developed massive bilateral lower extremity edema. Ultrasound confirmed bilateral left more than right iliofemoral DVT.
- Suspicion for filter thrombosis was confirmed by Ultrasound.
- Patient failed three to four weeks of Lovenox therapy, 1 mg per kg twice a day subcutaneous injections.



Procedure

- Patient was taken to cath lab for inferior vena cava reconstruction.



Results / Conclusion

- Few days following the procedure, the patient's edema significantly improved.
- Patient remains asymptomatic with lifetime of Coumadin therapy.

