


FOOT GANGRENE



Physician

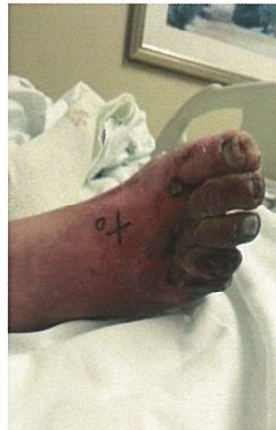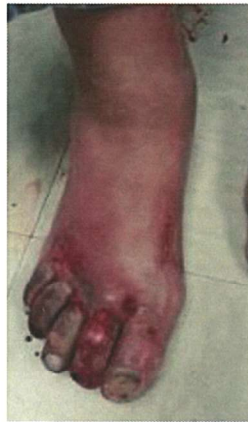Basel Refai, MD, RVT, RPVI, FSVM
Interventional Vascular Internist

Facility

Lake Martin Vein & Laser Center
Alexander City, AL 35010
256-212-9300
www.lakemartinvein.com

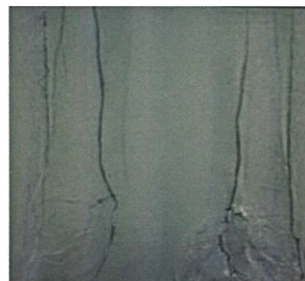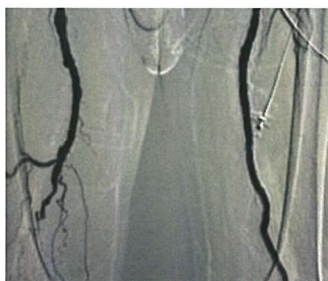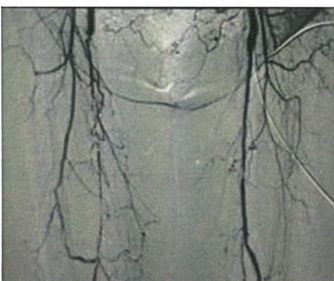
Clinical History

- 63 year old diabetic with end stage renal disease.
- Patient on hemodialysis.
- Presented to the office with two weeks history of wet gangrene.



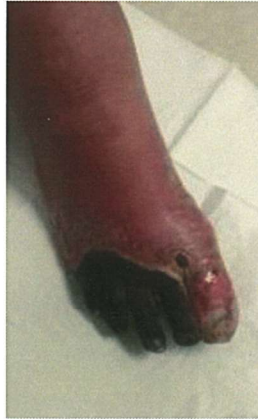Procedure

- Patient was taken to the cath lab immediately for re-vascularization.





- Found to have popliteal artery occlusion and severe below knee disease.
- Patient was re-vascularized using orbital atherectomy, balloon angioplasty and stenting to his popliteal artery and laser atherectomy balloon angioplasty to his below knee disease.



(after re-vascularization)

Results/Conclusion

- We were able to limit his amputation to transmetatarsal which kept his mobility intact.

