


ACUTE NECROTIC INFECTIOUS LIMB ISCHEMIA



Physician

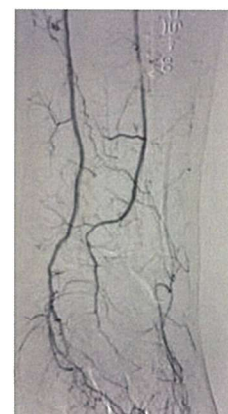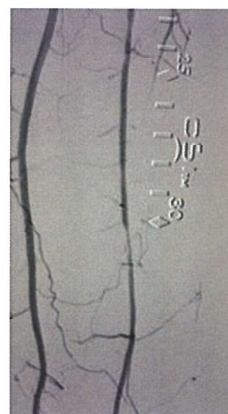
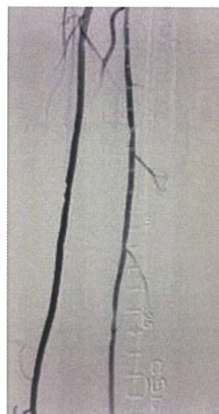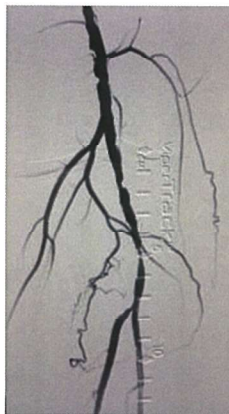
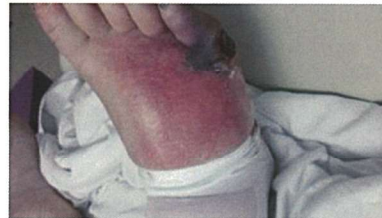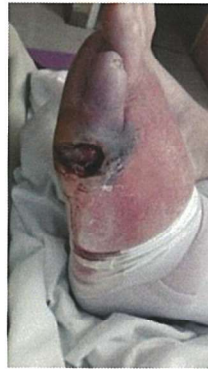Basel Refai, MD, RVT, RPVI, FSVM
Interventional Vascular Internist

Facility

Lake Martin Vein & Laser Center
Alexander City, AL 35010
256-212-9300
www.lakemartinvein.com

Clinical History

- 43 year old non-compliant.
- Risk profile is hypercholesterolemia and triglyceridemia on mixed drug therapy.
- Poorly controlled diabetes.
- Coronary artery disease.
- Presented with gangrene to the left fifth toe.
- With ischemic diabetic neurotrophic ulcer to right fourth metatarsal area.



Procedure

- Treated with endovascular therapy.
- Diffuse popliteal disease, peroneal artery disease and anterior tibial artery disease.
- Patient was treated with laser atherectomy and angioplasty.



Results / Conclusion

- Patient ended up having a six vessel CABG afterward.
- We were able to heal his fifth toe stump after amputation and also successfully able to heal his harvested vein graft sites to both legs.

