

ACUTE LIMB ISCHEMIA



Physician

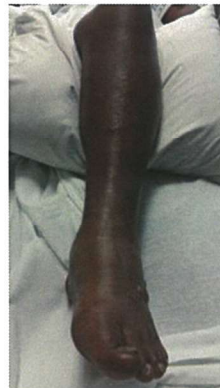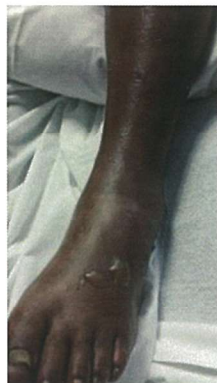Basel Refai, MD, RVT, RPVI, FSVM
Interventional Vascular Internist

Facility

Lake Martin Vein & Laser Center
Alexander City, AL 35010
256-212-9300
www.lakemartinvein.com

Clinical History

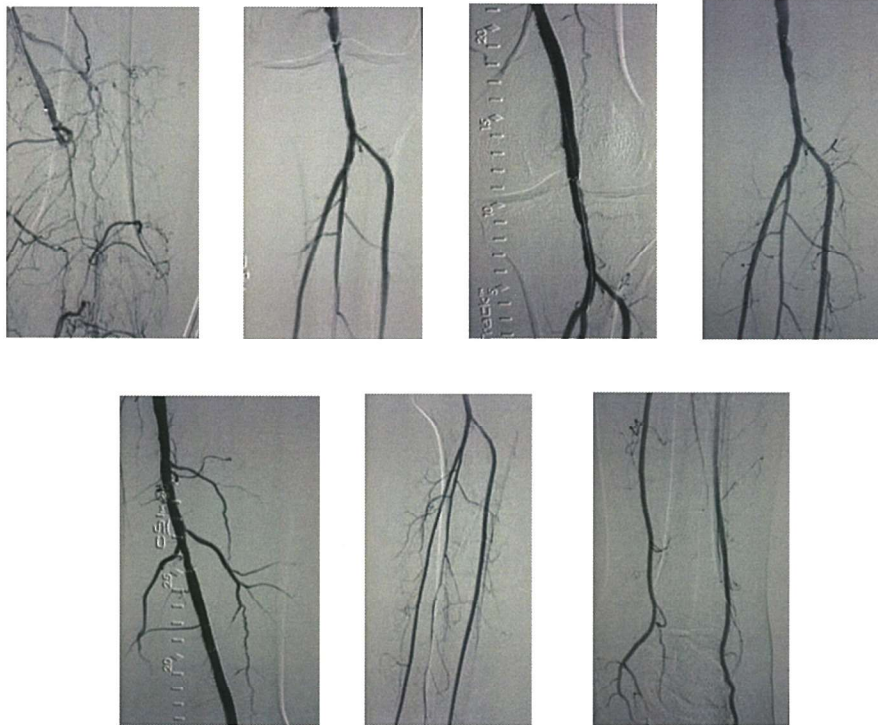
- 59 year old.
- Active smoker with moderately controlled hypertension and hyperlipidemia.
- Presented with two weeks history of acute limb iscehmia with multiple visits to the ER.
- Patient's primary care doctor noted skin blistering, loss of pulse of the dorsal foot.
- Patient was referred to our limb salvage center.
- Found to have acute spontaneous distal superficial femoral/popliteal arteries dissection with embolic debris below the knee.





Procedure

- Patient was treated with laser atherectomy, balloon angioplasty and stenting to popliteal segment and catheter directed thrombolytic therapy overnight to improve his outflow.



Results / Conclusion

- Patient's foot and leg was saved.

